


CASE REPORT

**NICARDIPIN ASSOCIATED PULMONARY EDEMA
A SEVERE COMPLICATION OF TOCOLYSIS
A CASE REPORT**

Dr Youssef Motiaa , MD ; Dr Wafae El Otmani, MD, Dr Nezha El oudghiri, MD ; Pr Anas Tazi Saoud, MD

Anesthesiology and intensive care department, Souissi maternity, Ibn Sina university hospital. Faculty of Medicine and Pharmacy. Mohammed V University. Rabat. Morocco.

ABSTRACT

In preterm labor, tocolytics are used to stop uterine contractions and to allow the administration of corticosteroids for fetal lung maturation, nicardipine is a calcium channel blocker increasingly used for this indication. Several adverse effects have been reported during tocolysis using nicardipine, one of the most serious complications is Acute Pulmonary Edema.

We report a case of a parturient who was admitted at 28 weeks pregnancy for preterm labor and developed a respiratory failure two days following tocolysis with nicardipine. Echocardiography and Computed Tomography Pulmonary Angiography (CTPA) ruled out a pulmonary embolism and a decompensated heart disease. The patient received oxygen therapy and diuresis for Acute Pulmonary Edema with favorable outcome.

The purpose of this paper is to discuss the risk factors for occurrence of pulmonary edema after tocolysis, importance of etiologic investigation to exclude differential diagnoses and therapeutic options for management of this complication.

KEY WORDS: Nicardipine, Tocolysis, Acute Pulmonary Edema.

Corresponding author:

Dr Motiaa Youssef, 140 Naim, Meknes, Morocco.

Email: youssefmotiaa@gmail.com Tel :(+212) 0671195295

Copyright © 2018 Dr Youssef Motiaa et al.

This is an open access article distributed under the [Creative Commons Attribution 4.0 International](https://creativecommons.org/licenses/by/4.0/), which permits unrestricted use, distribution, and reproduction in any medium, provided the original work is properly cited.

INTRODUCTION

Preterm labor is one of the principal causes of perinatal mortality and morbidity and carries significant risk of long term neurological sequelae in the survivors [1]. Tocolysis is used to stop uterine contractions to allow administration of corticosteroid therapy for lung maturation. Many agents are used for tocolysis: β 2-adrenergic agonists, calcium entry-blocking agents, magnesium sulfate, and non steroidal anti-inflammatory drugs [2]. It has been shown that calcium channel blockers are more effective than β 2 adrenergic agonists in terms of prolongation of pregnancy, serious neonatal morbidity and maternal side effects [3].

Calcium channel blockers replaced β 2-adrenergic agonists to reduce severe side effects such as acute pulmonary edema [4] which incidence is less than 1% in the general obstetric population [5]. Many cases of acute pulmonary edema associated to tocolytic agents were reported in the literature.

We report the case of Acute Pulmonary Edema complicating tocolysis with nicardipine for preterm labor in a 28 weeks pregnant woman, and we discuss necessary investigations to confirm the diagnosis and treatment options of this complication. The objective of this work is to report a neuroleptic-induced Brugada syndrome. To our knowledge, this is the first reported case of neuroleptic-induced Brugada syndrome Morocco. Hence the need to highlight the peculiarity of this disorder.

CASE REPORT

A 26 years old G1P0 parturient, with no past medical history was admitted to hospital for preterm labor at 28 weeks pregnancy without premature rupture of membranes. Tocolysis was started using intravenous infusion of Salbutamol (5 mg of salbutamol injected into 500 mL of 0.9% sodium chloride solution) then bi-daily nicardipine 50mg. 12 mg doses of Betamethasone were given intramuscularly 24 hours apart for fetal lung maturation. Two days after, the patient developed a

worsening shortness of breath with oxygen desaturation at 90% on room air, she was tachypnoeic, heart rate was 130 beats per min (bpm) and blood pressure was 120/60 mmHg. On auscultation, bilateral crackles were heard throughout lung fields, calves and thighs were soft and non tender. Laboratory investigation revealed normal White Blood Cell count (WBC) 9700/L, Hemoglobin 9.8g/dl, Urea 0.1g/l, Creatinine 3.7mg/dl, Sodium 134mmol/l, Potassium 3.6mmol/l, Calcium 2.23mmol/l, C-reactive protein 3.7mg/l. Vaginal swabs and urine cultures were negative. She was admitted to Intensive Care Unit given the clinical severity.

Chest X-ray showed bilateral interstitial and alveolar opacities and no pleural effusions (figure 1). The 12-lead electrocardiogram showed sinus tachycardia with no other abnormalities. Echocardiography showed normal systolic and diastolic Left Ventricular function (ejection fraction 73%) and no pulmonary hypertension. Lower limbs venous Doppler was normal.

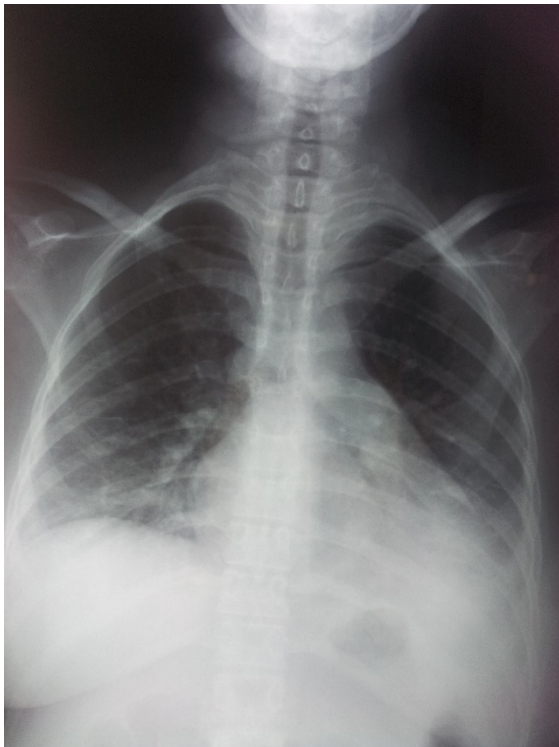

Figure 1: Chest X-ray showing bilateral interstitial and alveolar opacities and no pleural effusions

Nicardipine was stopped. The patient was seated in semi-upright position, received oxygen therapy and given intravenous Furosemide 120mg in 3 divided doses over the first 24hours with a good progress. CT Pulmonary Angiography ruled out a Pulmonary Embolism.

The Fetal Heart Rhythm and obstetrical ultrasound findings were normal.

The patient was discharged from Intensive Care Unit (ICU) to Obstetric unit after 2 days, and from hospital 5 days later. She has been given daily 40mg of Furosemide for 5 days.

On follow-up 2 weeks later, the patient was asymptomatic and repeat echocardiogram demonstrated normal heart function with no ventricular dilatation. The pregnancy ended with normal delivery at full term 39 weeks gestational age.

DISCUSSION

The use of nicardipine such as tocolytic agent is not harmless of complications; the acute pulmonary edema is a serious complication that may be encountered during the tocolysis by calcium channel blockers as reflected in this case report.

The most commonly used drugs for tocolysis are β 2-adrenoceptor agonists (ritodrine), calcium channel

blockers (nifedipine), oxytocin receptor antagonist (atosiban), prostaglandin inhibitors (indomethacin) and magnesium sulfate [5].

There is evidence suggesting that calcium-channel blockers are preferable to other drugs for tocolysis [6]. Calcium channel blockers were shown to have benefits over betamimetics with respect to prolongation of pregnancy, serious neonatal morbidity, and maternal adverse effects. Calcium channel blockers may also have some benefits over Oxytocin receptor antagonists (ORAs) and magnesium sulphate, although ORAs results in fewer maternal adverse effects [3]. They exert their tocolytic effect by blocking the opening of the channel and preventing the influx of extracellular calcium ions into the myometrial cell [5].

Acute pulmonary edema (APE) is a serious complication described during tocolysis, its incidence following the use of calcium channel blockers remains unknown although several observations have been published. The pathophysiology of APE during tocolysis by nicardipine remains unclear, but several risk factors have been identified: multiple pregnancy, spontaneous premature labor, association of tocolytic therapy, corticosteroids for fetal lung maturation, preeclampsia or HELLP syndrome, overhydration with isotonic saline solution, valvular heart diseases and infections (especially chorioamnionitis) [7,8]. Also, APE could be due to diastolic dysfunction, tachycardia and sodium and water retention secondary to sympathetic stimulation action of calcium channel blockers [9].

In this case, the patient had a mono-fetal uncomplicated pregnancy; no preeclampsia or heart diseases were diagnosed. However, the use of β 2-adrenergic agonists for tocolysis and corticosteroid therapy for fetal lung maturation were two associated risk factors of acute pulmonary edema. Also, our patient's gestational age was 28 weeks amenorrhoea when the peak of sodium and fluid retention is achieved.

Biological and radiological investigations have been performed to rule out the possibility of infection causing preterm labor, pulmonary embolism and a decompensated cardiac disease during pregnancy causing dyspnea.

The clinical presentation of this complication following tocolysis with nicardipine is not specific, for this reason some authors have suggested B-type natriuretic peptide measurement for early diagnosis and monitoring of pregnant women with acute pulmonary edema [10].

The treatment of the APE induced by nicardipine is based on discontinuation of the tocolytic agent and symptomatic treatment based on the Oxygen Therapy and diuretics. For patients with severe hypoxia, non invasive ventilation can be proposed as an alternative to endotracheal intubation. In this case, the patient has improved with symptomatic treatment (oxygen and diuretics) after stopping the nicardipine. Regarding the obstetric decision, Lower Segment Cesarean Section has not been made for two reasons: there were no signs of fetal distress and uterine contractions have stopped.

CONCLUSION

Nicardipine is more and more used for tocolysis, the APE remains a complication to fear in this situation especially in the presence of risk factors or complications of pregnancy. For these situations other drugs can be proposed.

AUTHORS' CONTRIBUTIONS

The draft was written by Youssef Motiaa and Wafae el Otmani and bibliographic research was done by Nezha el Oudghiri. All the steps of this work were directly supervised by S.A. Tazi.

PATIENT CONSENT

Written informed consent was obtained from the patient for publication of this case report.

COMPETING INTERESTS

The authors declare no competing interests.

REFERENCES

- [1] Johnson A, Townshend P, Yudkin P, Bull D, Wilkinson AR. Functional abilities at age 4 years of children born before 29 weeks gestation. *BMJ* 1993;306:1715-8.
- [2] Bolden JR. Acute and chronic tocolysis. *Clin Obstet Gynecol*. 2014 Sep;57(3):568-78.
- [3] Flenady V, Wojcieszek AM, Papatsonis DN, Stock OM, Murray L, Jardine LA et al. Calcium channel blockers for inhibiting preterm labour and birth. *Cochrane Database Syst Rev*. 2014 Jun 5;(6):CD002255.
- [4] Seror J, Lefevre G, Berkane N, Richard F, Bornes M, Uzan S et al. B-type natriuretic peptide measurement for early diagnosis of acute pulmonary edema during pregnancy. *Acta Obstet Gynecol Scand*. 2014 Dec;93(12):1317-9.
- [5] Choi HS, Choi H, Han S, Kim HS, Lee C, Kim YY, et al. Pulmonary edema during pregnancy: unilateral presentation is not rare. *Circ J*. 2002 Jul;66(7):623-6.
- [6] van Vliet EO, Boormans EM, de Lange TS, Mol BW, Oudijk MA. Preterm labor: current pharmacotherapy options for tocolysis. *Expert Opin Pharmacother*. 2014 Apr;15(6):787-97.
- [7] King JF, Flenady VJ, Papatsonis DN, Dekker GA, Carbone B. Calcium channel blockers for inhibiting preterm labour. *Cochrane Database Syst Rev* 2003; 1: CD002255.
- [8] Oei SG. Calcium channel blockers for tocolysis: a review of their role and safety following reports of serious adverse events. *Eur J Obstet Gynecol Reprod Biol* 2016;126:136-45.
- [9] Akerman G, Mignon A, Tsatsaris V, Jacqmin S, Cabrol D, Goffinet F. Pulmonary edema during calcium-channel blockers therapy: Role of predisposing or pharmacologic factors? *Journal de Gynecologie Obstetrique et Biologie de la Reproduction*. 2007;36(4):389-392.
- [10] Serena C, Begot E, Cros J, Hodler C, Fedou AL, Nathan-Denizot N et al. Nicardipine-induced acute pulmonary edema: a rare but severe complication of tocolysis. *Case Rep Crit Care*. 2014;2014:242703.
- [11] Seror J, Lefevre G, Berkane N, Richard F, Bornes M, Uzan S et al. B-type natriuretic peptide measurement for early diagnosis of acute pulmonary edema during pregnancy. *Acta Obstet Gynecol Scand*. 2014 Dec;93(12):1317-9.