

CLINICAL CASE

Holt-Oram Syndrome : A Simple Diagnosis That Is Often Delayed ATwo Cases Report.

Dr Bakkali Abderrahmane, MD, Dr Harrag Jamal Eddine, MD, Dr Koulekey Dodji, MD, Dr Benlafqih Chakib, MD, Dr Sayeh Rochd, MD, Pr Mohamed Laaroussi, MD.
Department of Cardiovascular surgery "A", Ibn Sina Hospital, Rabat, Morocco.

Received 06 Septembre 2014; Revised 11 Septembre 2015; Accepted 19 September 2015.

ABSTRACT

Holt-Oram syndrome is uncommon. It is characterized by heart disease and skeletal abnormalities of the hands and arms (upper limbs). This condition is inherited in an autosomal dominant pattern, which means one copy of the altered gene in each cell is sufficient to cause the disorder. The most common problem is an atrial septal defect, and upper limb musculoskeletal deformities. These morphological characteristics should suggest a cardiac abnormality which is usually silent.

We report isolated cases with this syndrome. Two patients with skeletal anomalies have been survived 11 and 29 years with their congenital cardiac defects without being diagnosed in despite of their obvious upper limbs deformities. In the two cases, the diagnosis of Holt-Oram syndrome was delayed and the cardiac defects have been revealed at the stage of surgery. We will discuss the variables of the musculoskeletal abnormalities and their association with the cardiac morphological defects.

Holt-Oram syndrome is a rare inherited clinical disorder. Cardiac defect should be suspected in the presence of congenital upper limb abnormalities.

KEY WORDS: Holt-Oram syndrome, Congenital heart disease, Musculoskeletal abnormalities.

Corresponding author:

Dr Abderrahmane Bakkali, Department of Cardiovascular surgery "A", Ibn Sina Hospital, Agdal 10170 Rabat, Morocco.
E-mail: drbakkaliabd@yahoo.fr. Phone: +212661291450.

Copyright © 2015 Bakkali Abderrahmane et al.

This is an open access article distributed under the [Creative Commons Attribution License](https://creativecommons.org/licenses/by/4.0/), which permits unrestricted use, distribution, and reproduction in any medium, provided the original work is properly cited.

INTRODUCTION

Holt-Oram syndrome is a rare congenital disorder involving the hands, arms, and the heart. Its incidence is one in 100,000 live births [1]. It is an autosomal dominant condition characterized by upper limbs deformities, thumb abnormalities, in particular and cardiac malformations, especially atrial septal defects [2].

We report two cases of this syndrome, which were diagnosed late and we will discuss the variables of the musculoskeletal abnormalities and their association with the cardiac defects.

CASES REPORT

Patient 1: A 29 year-old Moroccan man was transferred to our department for atrial septal defect. Physical examination revealed pectus excavatum, prominent kyphosis, stiff elbows, short left forearm, hypoplastic left and right thenar, syndactyly of the left thumb and the index finger and triphalangeal left thumb with abnormal implantation (figure: 1, 2).

Auscultation revealed a loud systolic murmur at the left sternal margin, fixed splitting of the second heart sound (S2) and diastolic murmur of tricuspid regurgitation. The ECG showed sinus rhythm with hypertrophy of the right

atrial and the right ventricle with right axis deviation. The chest x-ray showed severe right atrial and right ventricular dilatation and marked bilateral central pulmonary arterial distension. Echocardiography revealed a large secundum atrial septal defect and moderate tricuspid regurgitation. The mean pulmonary artery pressure was 50 mm Hg with enlarged right chambers.

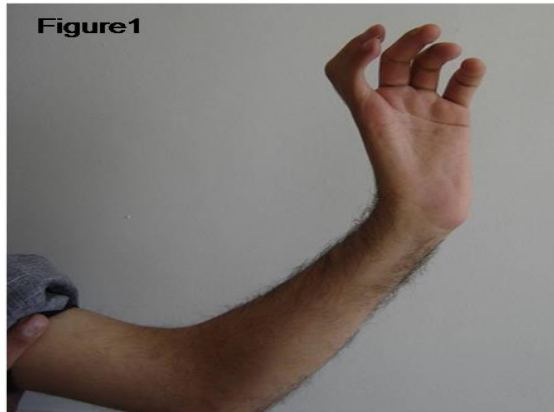


Figure 1: hypoplastic left and right thenar, syndactyly of the left thumb and the index finger.

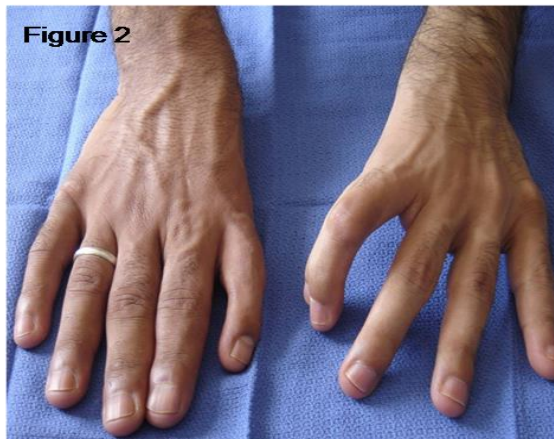

Figure 2: syndactyly of the left thumb and the index finger and triphalangeal right thumb with abnormal implantation.

Patient 2:

An asymptomatic 11-year-old boy presented with an atrial septum defect. On clinical examination; hypoplastic scapula, short clavicle, pectus carinatum; kyphosis, absent thumbs, hypoplastic radii and bilateral complete limitation of supination movements were noted (figure: 3). His heart auscultation showed fixed splitting of the second heart sound (S2) and a systolic murmur 5+/6+ at the left parasternal area. Electrocardiogram showed normal sinus rhythm with right ventricular hypertrophy with right axis deviation. The chest X-ray showed cardiomegaly mainly of the right atrium and the right ventricle and increased pulmonary vascular markings. Echocardiography showed a large ostium secundum atrial septal defect with dilated right cavities and high pulmonary pressure.

In two cases, no similar morphological features in family members have been noted.

Both patients underwent surgical closure of atrial septal defect during routine extracorporeal circulation. In the first case, De Vega annuloplasty was performed. The postoperative period was uneventful and the two patients

were discharged home in good clinical condition after proposing genetic counseling.

After follow-up period of two years for the first case and one year for the second, both patients were asymptomatic.

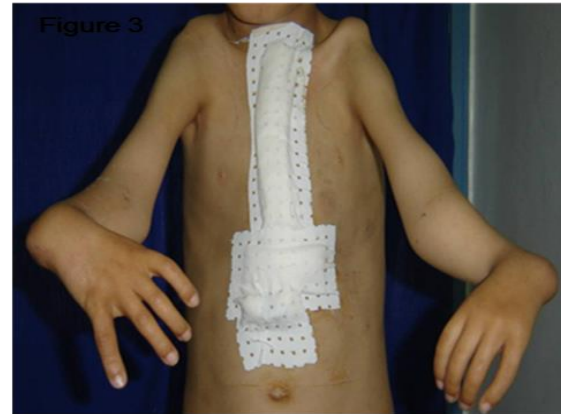


Figure 3: patient operated for ASD presenting hypoplasia of clavicles, hypoplastic radii, bilateral complete limitation of supination movements and absent thumbs.

DISCUSSION :

Holt-Oram syndrome was first described by Mary Holt and Samuel Oram in 1960 as an association of familial heart disease and musculoskeletal abnormalities. One year later it was named by Victor McKusick, when describing a similar case [2, 3]. Since then, different authors have reported on approximately 200 patients [4, 5]. The association of Cardiac and upper limb abnormalities has inspired a series of names for this syndrome; such as "atriodigital dysplasia", "heart-hand syndrome", "heart upper-limb syndrome", "upper-limb cardiovascular syndrome", "Cardiac-limb syndrome", and "cardiomelic syndrome". However, it is Holt-Oram syndrome, which remained in common use[4-6]. It is an autosomal dominant disorder, caused by a translocation with a breakpoint at chromosome 12q24.1 that inactivate the TBX5 gene, which participate in the specification of left/right ventricles and ventricular septum position during cardiogenesis [1, 6, 7]. The prevalence of Holt-Oram syndrome is approximately one per 100,000 births [1].

The syndrome is inherited as an autosomal dominant trait occurring in families, but the literature also provides isolated case reports. Smith and al reported 15 isolated cases which were considered to be new mutations [8]. In nearly 40% of cases there are new mutations [9]. The cases we presented seem to be sporadic because their parents, sisters and brothers were apparently healthy.

The typical combination is considered to be a triphalangeal thumb with a secundum atrial septal defect [5], but the clinical expression varies widely. There is a great range in the severity of both the heart and musculoskeletal lesions. Skeletal abnormalities spare the lower limbs. This occurs because the mutant gene interferes with the embryonic differentiation during the 4th and 5th weeks of pregnancy, when the lower limbs are not yet differentiated [4, 10].

Upper limb deformity covers a wide range of anomalies extending from minor abnormalities to phocomelia. The thumb is the most commonly affected structure. It can be displaced, absent, hypoplastic or triphalanged and is usually associated with hypoplastic thenar, hypoplastic, absent or extra fingers, syndactyly, anomalies of the carpus, radial aplasia or limited supination of the forearm. Upper extremity deformity is in the preaxial radial ray distribution, usually bilateral, yet may be asymmetrical in

severity, the left side usually being the worst [2, 4, 9, 11, 12].

Other less common skeletal abnormalities include hypoplasia of the clavicles and shoulders, chest wall anomalies such as deficient pectoral muscles, pectus excavatum or carinatum [5, 11]. Also rib and vertebral anomalies have been reported.

This variable phenotypic expression was observed in our cases. Diversity in the expression of abnormalities seems to be attributed to different gene mutations [6].

The most frequent cardiac abnormalities are atrial septal defect, followed by ventricular septal defect [2, 11, 13]. Other less common cardiac associations include pulmonary stenosis, mitral valve prolapse, Persistent ductus arteriosus, anomalous coronary arteries, persistent left superior vena cava [9, 11].

Complex cardiac lesions such as tetralogy of Fallot, double outlet right ventricle and total anomalous pulmonary venous return are also noted in subjects with the Holt Oram syndrome [1, 11]. Electrocardiographic abnormalities range from asymptomatic conduction disturbance to variable degree of atrioventricular block [1].

The diagnosis is not difficult. Strict diagnostic criteria include the presence of preaxial radial ray malformation of at least one upper limb along with a personal or a family history of septation defects and/or atrioventricular conduction disease [14]. Prenatal diagnosis using ultrasound in the second trimester is possible [12]. The differential diagnosis will include VATER syndrome, Roberts's syndrome and Fanconi pancytopenia [5]. Remarkably, our patients had a typical cardiac defect of Holt-Oram syndrome (atrial septal defect) but the diagnosis was delayed at the stage of surgery.

CONCLUSION :

Holt-Oram syndrome is a rare congenital association of heart disease and musculoskeletal abnormalities. The presence of upper limb congenital deformities particularly thumb anomalies, which are easily identifiable, would indicate screening for cardiac defects. The prognosis depends upon the identification and treatment of cardiac defects.

AUTHORS' CONTRIBUTIONS

The participation of each author corresponds to the criteria of authorship and contributorship emphasized in the [Recommendations for the Conduct, Reporting, Editing, and Publication of Scholarly work in Medical Journals](#) of the [International Committee of Medical Journal Editors](#). Indeed, all the authors have actively participated in the redaction, the revision of the manuscript and provided approval for this final revised version.

ACKNOWLEDGEMENT

Declared none.

PATIENT CONSENT

Written informed consent was obtained from patients for publication of this case report and any accompanying images. A copy of the written consent is available for review by the Editor-in-Chief of this journal.

COMPETING INTERESTS

The authors declare no competing interests.

REFERENCES :

- [1] Kumar R, Mahapatra SS, Datta M, Hoque A, Datta S, Ghosh S, et al. Holt-oram syndrome in adult presenting with heart failure: a rare presentation. *Case reports in cardiology*. 2014;2014:130617.
- [2] Holt M, Oram S. Familial heart disease with skeletal malformations. *British heart journal*. 1960;22(2):236.
- [3] McKusick VA. Medical genetics, 1959. *Journal of chronic diseases*. 1960;12:1-202.
- [4] Frota Filho JD, Pereira W, Leiria TL, Vallenias M, Leaes PE, Blacher C, et al. Holt-Oram syndrome revisited. Two patients in the same family. *Arquivos brasileiros de cardiologia*. 1999;73(5):429-34.
- [5] Hurst JA, Hall CM, Baraitser M. The Holt-Oram syndrome. *Journal of medical genetics*. 1991;28(6):406-10.
- [6] Basson CT, Huang T, Lin RC, Bachinsky DR, Weremowicz S, Vaglio A, et al. Different TBX5 interactions in heart and limb defined by Holt-Oram syndrome mutations. *Proceedings of the National Academy of Sciences of the United States of America*. 1999;96(6):2919-24.
- [7] Horb ME, Thomsen GH. Tbx5 is essential for heart development. *Development (Cambridge, England)*. 1999;126(8):1739-51.
- [8] Smith AT, Sack GH, Jr., Taylor GJ. Holt-Oram syndrome. *The Journal of pediatrics*. 1979;95(4):538-43.
- [9] Araujo Filho R, Alves PM, Carakushansky G, Maranhao EA, da Silva JA. [The Holt-Oram syndrome with patency of the common AV canal, complete form. Report of a case]. *Arquivos brasileiros de cardiologia*. 1983;40(6):397-402.
- [10] Chryssostomidis G, Kanakis M, Fotiadou V, Laskari C, Kousi T, Apostolidis C, et al. Diversity of congenital cardiac defects and skeletal deformities associated with the Holt-Oram syndrome. *International journal of surgery case reports*. 2014;5(7):389-92.
- [11] Basson CT, Cowley GS, Solomon SD, Weissman B, Poznanski AK, Traill TA, et al. The clinical and genetic spectrum of the Holt-Oram syndrome (heart-hand syndrome). *N Engl J Med*. 1994;330(13):885-91.
- [12] Sinha R, Nema C. Rare cardiac defect in Holt-Oram syndrome. *Cardiovascular journal of Africa*. 2012;23(2):e3-4.
- [13] Singh B, Kariyappa M, Vijayalakshmi IB, Nanjappa MC. Holt-oram syndrome associated with double outlet right ventricle: A rare association. *Annals of pediatric cardiology*. 2013;6(1):90-2.
- [14] McDermott DA, Bressan MC, He J, Lee JS, Aftimos S, Brueckner M, et al. TBX5 genetic testing validates strict clinical criteria for Holt-Oram syndrome. *Pediatric research*. 2005;58(5):981-6.