


CLINICAL STUDY

Is Hip Spica an Obsolete Method for Paediatric Femur Fractures? - A Retrospective Analysis of 58 Patients

Yadav Umesh , Sheoran Ajay, Bansal Himanshu, Devgan Ashish, Dahiya Amit, Mittal Ankit, Dutta Mayank, Ajay Singh
Orthopaedics, House no-16/11J, Medical Campus, PGIMS, Rohtak-124001, India

ABSTRACT

Background- Diaphyseal femur fracture in paediatric age group are common in orthopaedics with treatment options varying from conservative methods such as hip spica to operative measures such as nailing/plating. We analyzed results of patients treated conservatively in a hip spica cast. **Material and Methods-** 58 patients, upto 5 years of age, with shaft femur fracture managed by hip spica cast were retrospectively analysed in terms of healing clinically and radiologically and complications noted, if any. **Results-** Fracture healed satisfactorily in all patients. Mean age of patients affected was 3.8 years. Males were more affected and road side accident was most common etiology. Mean hospital stay was 3.4 days. Most common complication was skin breakage (27.58%) followed by cast soiling or breakage (13.79%) while shortening was seen in 3 patients (5.1%) and angulation in 2 patients (3.44%). **Conclusion-** Despite newer and safer implants, hip spica remains safe and cost effective method for treatment of femur fracture in children.

KEYWORDS: Hip Spica; Femur fractures; Paediatrics; Conservative.

Correspondence: Dr Yadav Umesh, Orthopaedics, House no-16/11J, Medical Campus, PGIMS, Rohtak-124001, India.

Email: drumeshyadav735@gmail.com

Copyright © 2020 Umesh Y et al. This is an open access article distributed under the [Creative Commons Attribution 4.0 International](https://creativecommons.org/licenses/by/4.0/), which permits unrestricted use, distribution, and reproduction in any medium, provided the original work is properly cited.

INTRODUCTION

Paediatric femur fractures, one of the common lower extremity fractures are encountered in orthopaedics with an incidence of 1.6% [1]. The incidence is on a rise due to the increase in road traffic accidents worldwide. Despite the advancements in pediatric orthopaedic surgical implants and techniques, hip spica cast still remains an effective and affordable treatment option, especially in developing countries like India. The literature recommends use of spica casting for pediatric shaft femur fractures between the ages of six months and five years [2]. They can also be managed either conservatively or operatively depending on patient profile, age of patient and fracture pattern [3]. Here we present our experience of 58 patients with femoral shaft fractures treated by immobilization in hip spica cast.

MATERIALS AND METHODS

In the present study we included all children of ages six months to 5 years with shaft of femur fracture that presented to us in last 42 months who were treated by hip spica cast and retrospectively analysed radiologically and clinically. Those with pathological fracture and with age more than 5 years were excluded from study group. Fractures of proximal and distal femur were also excluded from the group. All 58 patients were hemodynamically stable and treated by hip spica cast. Spica cast was applied on spica table and check X-rays were done to look for satisfactory reduction. Follow up were done at regular

intervals of 2 weeks and spica was removed after radiological evidence of union. The patients were then allowed gradual mobilization and weight bearing with range of motion exercises at hip and knee.

RESULTS

Mean age of patient was 3.8 years ranging from 8 months to 5 years. There was slight predominance of right side (55.17%) as compared to left (44.82%). Males were 1.3 times more commonly affected than females. 79.3% cases were result of road side accident while rest injuries were sustained due to fall. Mean hospital stay was days ranging from 1-7 days. Regarding fracture pattern, transverse fractures were most common (41.3%) followed by spiral type (34.4%) and oblique type (24.1%).

On sequential follow up, shortening was seen in 3 patients with 14 mm in two patients and 16 mm in another. Although no specific fracture location / pattern can be attributed to those but in both the patients, spica was applied twice due to soiling and breakage. However no such correlation is documented in literature. Angulation as a complication was also noted in two patients which was significant clinically and radiologically. The most commonly reported complication from spica casting for paediatric femur fractures has been skin related complications like abrasions or pressure sore. In our study less than one third patients had skin related issues (27.58%). Although most healed satisfactorily without any interventions. Cast breakage due to soiling was seen in

13.79% patients out of which half of the patients required reapplication of cast while reinforcement worked in rest of the patients. (Figure 1).

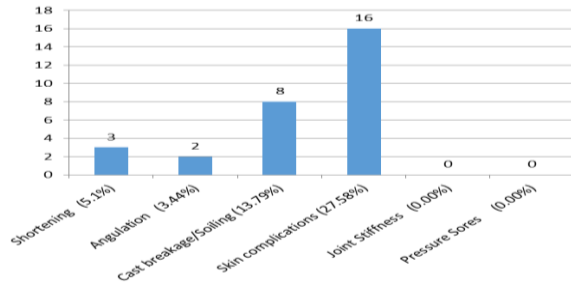


Figure 1: Complications of Hip Spica Cast Application.

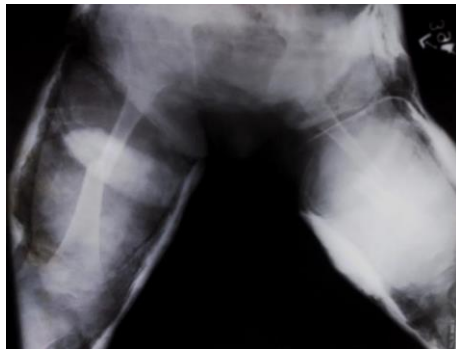

Figure 2: Antero-posterior radiograph of a patient with bilateral femur fracture immediately after hip spica application

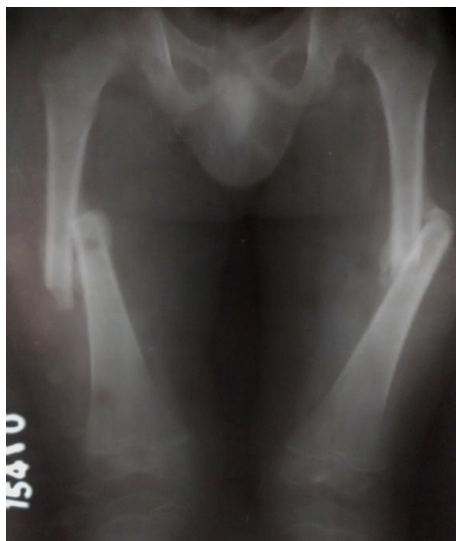

Figure 3: Radiograph showing callus formation in bilateral femur fracture at 3 months follow-up

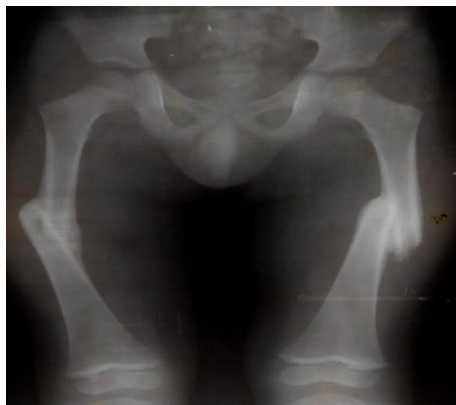

Figure 4: Radiograph of bilateral femur fracture at 5 months follow-up

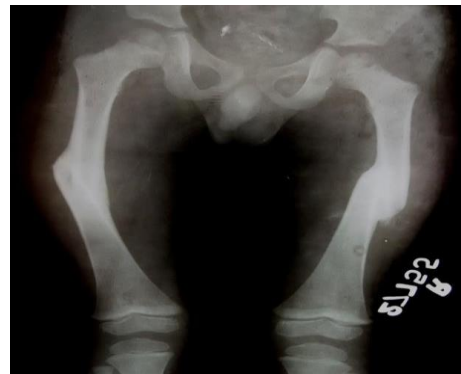

Figure 5: Radiograph of bilateral femur fracture at 7 months follow-up

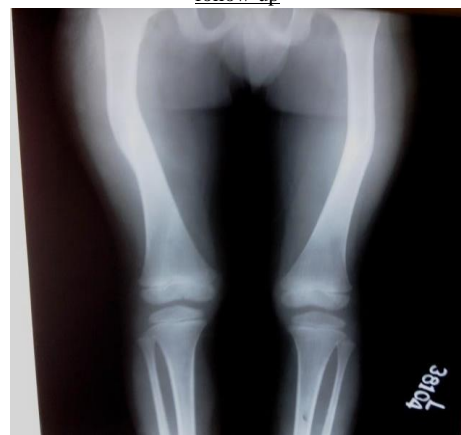

Figure 6: Radiograph of bilateral femur at 13 months follow-up showing radiological union

Table 1: Study Results

| Parameter | Value (n=58) |
|------------------------------|--------------|
| Mean Age (Years) | 3.8 |
| Side | |
| Right | 32 (55.17%) |
| Left | 26(44.82%) |
| Sex | |
| Male | 40 (68.96%) |
| Female | 18 (31.03%) |
| Mechanism | |
| Road side accident | 46 (79.3%) |
| Fall | 12(20.6%) |
| Mean Hospital Stay (Days) | 3.4 (1-7) |
| Fracture pattern- Transverse | 24 (41.3%) |
| Spiral | 20 (34.4%) |
| Oblique | 14 (24.1%) |

DISCUSSION

Treatment options for paediatric diaphyseal fractures vary from conservative to open reduction and internal fixation. Conservative methods includes immediate hip spica cast, traction followed by spica cast while operative interventions includes close reduction and osteosynthesis with plates/ intramedullary nails [4,5].

Since ancient times, spica cast has been used as effective treatment modality for paediatric diaphyseal fractures of femur. Numerous studies in past also reported excellent healing in children less than 5 years of age with spica casting alone. Road traffic accident still remains the most important cause of femur fracture in children. Male predominance and mean hospital stay 3.4 days is consistent with previous studies [6,7].

Table 2: Comparison of the complication rate in the present study with studies in the past

| Study (Year) | Total patients | Shortening | Angulation | | |
|----------------------------|----------------|------------|------------|------------|-----------|
| Epps et al (2006) [8] | 45 | 5 (11.1%) | - | - | 5 (11.1%) |
| Mansour et al (2010) [9] | 100 | - | 26 (26%) | 13 (13%) | 6 (6%) |
| DiFazio et al (2011) [10] | 300 | - | 5 (1.6%) | 77 (25.7%) | 24 (8%) |
| Ruhullah et al (2014) [11] | 25 | - | 1 (4%) | 3 (12%) | 1 (4%) |
| Present study | 58 | 3(5.1%) | 2(3.44%) | 16(27.58%) | 8(13.79%) |

As evident from above table, shortening is a complication which varies from zero to as high as 11.1% as described by Epps et al in 2006 [8]. The American Academy of Orthopaedic Surgeons Guidelines for the management of diaphyseal femur fractures in the paediatric population is to use spica casting for those with < 2 cm of shortening [3]. Angulation is another problem reported in literature with rates varying from 1.6% to 26%. Approximately 16° varus or valgus is accepted for patients under two years old, decreasing to 6° for adolescents treated with a spica cast. Still the most common complication remains skin breakage which is repeatedly reported in literature. Due to poor hygiene, soiling of cast and further breakage is also seen which may require another cast application. However other than socio-economic impact, no significant effect on healing is noted because of reapplication of cast. Although our study have few limitations like small sample size but still its results are consistent with the literature and proves that hip spica have excellent outcome in treating paediatric femoral fractures.

CONCLUSION

For developing countries like India, conservative methods like hip spica remains an effective yet affordable treatment

modality for treating paediatric femoral diaphyseal fractures despite few complications like angulation and shortening. Although surgical intervention is associated with better and early rehabilitation but noninvasive methods like spica are associated with fewer complications and equally effective functional outcome.

ACKNOWLEDGMENTS

None.

AUTHORS' CONTRIBUTIONS

The participation of each author corresponds to the criteria of authorship and contributorship emphasized in the [Recommendations for the Conduct, Reporting, Editing, and Publication of Scholarly work in Medical Journals of the International Committee of Medical Journal Editors](#). Indeed, all the authors have actively participated in the redaction, the revision of the manuscript, and provided approval for this final revised version.

COMPETING INTERESTS

The authors declare no competing interests with this case.

FUNDING SOURCES

None.

REFERENCES

- [1] Beaty, James H.; Kasser, J.R. Rockwood & Wilkins' Fractures in children. Sixth ed. Postgraduate medicine. Baltimore: Lippincott Williams & Wilkins, 2006.
- [2] Kocher MS, Sink EL, Blasler DR, Luhmann SJ, Mehlman CT, Scher DM et al. Treatment of pediatric diaphyseal femur fractures. JAAOS- Journal of the American Academy of Orthopaedic Surgeons. 2009;17(11):718-25.
- [3] Richmond J, Hunter D, Irrgang J, Jones MH, Snyder-Mackler L, Van Durme D et al. American Academy of Orthopedics Surgeons: American Academy of Orthopaedic Surgeons clinical practice guideline on the treatment of osteoarthritis (OA) of the knee. J Bone Joint Surg Am. 2010;92(4):990-3.
- [4] Coyte PC, Bronskill SE, Hirji ZZ, Igle-Takacs G, Treise BS, Wright JG. Economic evaluation of 2 treatments for pediatric femoral shaft fractures. Clin Orthop Relat Res. 1997;336:205-215.
- [5] Kasser JR. Femur fractures in children. Instr Course Lect. 1992;41:403-408.
- [6] Irani RN, Nicholson JT and Chung SMK. Long term result in the treatment of femoral shaft fractures in young children by immediate spica immobilization. J Bone Joint Sur 1976;58A: 945-51.
- [7] Sugi M and Cole WG. Early plaster treatment for fractures of the femoral shaft in childhood. J Bone Joint Surg 1987;69B :743-5.
- [8] Epps HR, Molenaar E, O'Connor DP. Immediate single-leg spica cast for paediatric femoral diaphysis fractures. J Pediatr Orthop 2006;26:491-496.
- [9] Mansour AAS III, Wilmoth JC, Mansour AS, et al. Immediate spica casting of pediatric femoral fractures in the operating room versus the emergency department: comparison of reduction, complications, and hospital charges. J Pediatr Orthop 2010;30:813-817.
- [10] DiFazio R, Vessey J, Zurakowski D, Hresko MT, Matheny T. Incidence of skin complications and associated charges in children treated with hip spica casts for femur fractures. J Pediatr Orthop 2011;31:17-22.
- [11] Ruhullah M, Singh HR, Shah S, Shrestha D. Primary hip spica with crossed retrograde intramedullary rush pins for the management of diaphyseal femur fractures in children: a prospective, randomized study. Niger Med J 2014;55:111-115