


**CASE REPORT**

# **Idiopathic Harlequin Syndrome in a Young Women during Physical Exercise: A Case Report and Literature Review**

Amal Hajjij <sup>a</sup> , Madiha El Jazouli <sup>b</sup>, Othman Haddani <sup>a</sup>, Fouad Benariba <sup>a</sup>

<sup>a</sup>Department of otolaryngology, Head and Neck surgery, Cheikh Khalifa International University Hospital; Faculty of Medicine, Mohamed VI University of health sciences (UM6SS), Casablanca, Morocco

<sup>b</sup>Department of Dermatology, Cheikh Khalifa International University Hospital; Faculty of Medicine, Mohamed VI University of health sciences (UM6SS), Casablanca, Morocco

## **ABSTRACT**

The Harlequin syndrome is a rare and benign disorder of the sympathetic nerves that is mostly idiopathic. It is characterized by an erythema associated with an intense sweating of one side of the face, and a pallor and anhidrosis of the other side. A complete workup to rule out secondary organic causes should be done properly. The medical or surgical options are only required if the patient is in demand of treatment. Psychological and social impacts of this condition should be considered while consulting patients for treatment options. We report a case of a 24 years old female patient who presented this syndrome during exercise and heat stress. She improved considerably after botulinum toxin injections.

**KEYWORDS:** Harlequin Syndrome; Sympathetic Nerves; Erythema; Face; Botulinum Toxin.

**Correspondence:** Dr Amal Hajjij, Department of Otolaryngology, Head and Neck surgery, Cheikh Khalifa International University Hospital, Bld Mohammed Taïeb Naciri, Commune Hay Hassani 82 403, Casablanca, Morocco.

Email: [ahajjij@um6ss.ma](mailto:ahajjij@um6ss.ma).

**Copyright © 2020 Hajjij A et al.** This is an open access article distributed under the [Creative Commons Attribution 4.0 International](https://creativecommons.org/licenses/by/4.0/), which permits unrestricted use, distribution, and reproduction in any medium, provided the original work is properly cited.

## **INTRODUCTION**

The Harlequin syndrome is a unilateral dysautonomic disorder of the hemiface. It is caused by a deficit of the sympathetic system that is expressed during effort by facial palor and anhidrosis of the pathologic hemiface, meanwhile the other hemiface present intense erythema and hyperhidrosis. It is a rare and benign disease that is more frequent in the female population and is mostly idiopathic. In this article we submit a case of this rare condition in young women with a review of literature.

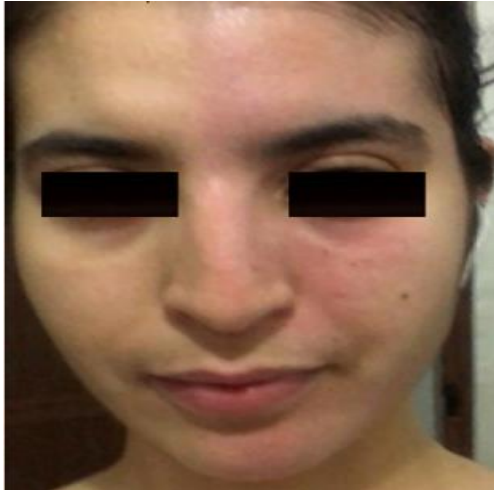## **CASE REPORT**

Our patient is a 24 years old female, without any notable antecedent. She doesn't have history of trauma, cervicothoracic surgery or neuropathy. She presented to the ENT clinic with a left side hemifacial flush with excessive sweating of the same side mainly occurring during effort and exercise. Meanwhile, there was an absence of erythema on the right side of the face (Figure 1). During clinical examinations at rest, there was no

cutaneous abnormalities or an asymmetry of the face. The neurological examination was totally normal, there was no abnormalities of the cranial nerves and no motor or sensory deficit. The ophthalmic examination did not find any pupillary irregularity or any ptosis. An initial workup and magnetic resonance imaging (MRI) of the brain and the spine were performed and the results showed no abnormalities on thoracic sympathetic chain.

With these typical clinical signs and the absence of lesions on the MRI, the diagnosis of idiopathic Harlequin syndrome was made.

After the diagnosis was retained, the patient was very demanding of treatment. We suggested regular botulinum toxin injections subcutaneously once every 3 to 6 months. She showed a significant improvement of her symptoms and has been regularly followed up for 9 months until the date of submission.



**Figure 1:** 24 years old with erythema of the left side of the face and pallor of the right side.

## DISCUSSION

The Harlequin syndrome is a newly discovered disorder, it was described for the first time by Lance et al in 1988 (1). They reported five cases of the syndrome, with unilateral sweating and flushing of the hemiface during emotional stress, hot weather or intensive effort (1). The vasomotor disorder and the sweating is caused by a denervation of the sympathetic fibres of the face with unilateral blocking of the nerves influx. The origin of these fibres is in the hypothalamus inside the brain. These fibres synapse in the lateral horn of the cervico-thoracic spinal cord, this is known as the first order neuron of the sympathetic system (2). Then it synapses with the second order neuron (pre-ganglionic) at the T2-T3 roots. The nerves then exit the spinal cord and progress through the sympathetic chain in the thoracic region. In the superior cervical ganglion, the second neuron binds with the third. It then travels inside the carotid plexus before arriving at the hemiface and proceed to the vasomotor effects (2). An ipsilateral lesion in the path of the fibres gives a deficiency of the vasodilatation activity on the same side of the face associated with lack of sweating. On the other side the sympathetic system is trying to correct the contra-lateral deficit by increasing its activity which result in an excessive flushing with high intensity sweating (2).

The Harlequin syndrome can be secondary to a lesion in the path of the sympathetic fibres. That is why a computerized tomography scan (CT-scan) of the chest and Magnetic resonance imaging (MRI) of the hypothalamus and the cervico-thoracic spine should always be performed in order to eliminate an organic lesion.

If a lesion is found a Claude-Bernard-Horner syndrome can be confused with a Harlequin syndrome. So, it is important to differentiate the two disorders during the clinical examination. The Horner syndrome associate the unilateral erythema of the face with ophthalmic disorders as ptosis and miosis. Meanwhile there is no ophthalmic abnormalities in the Harlequin syndrome (2). The disorder is commonly idiopathic without any organic lesion found. Indeed, some idiopathic cases of Harlequin syndrome have been described in the literature, mainly caused by exercise and revealed by stress test (3, 4). Physical examination and imaging were normal, which is in concordance with the case we describe.

In some very rare cases, Harlequin syndrome could be the first manifestation of a neurological diseases as diabetes neuropathy, Guillain-Barré syndrome, syringomyelia and multiple sclerosis (2).

There were some cases reported of iatrogenic Harlequin syndrome secondary to cervico-thoracic surgeries. There is the case of a 6 years old patient that presented a ganglioneuroma in the right upper mediastinum. the mass was originated from the sympathetic chain. During surgery they resected the mass associated with sympathetic fibres of the T2 level. In the post-operative recovery unit, they noticed an intense flush of the contra-lateral side of the face and sweating that intensifies when the patient cried. The post-operative neurological examination was normal; no ptosis neither miosis were associated (5).

There is also another case of a 11 years old male patient that presented a right neck schwannoma that was excised. After the operation the boy presented a Harlequin syndrome associated with Horner signs. (6).

Beside of adult cases, the idiopathic Harlequin syndrome can be found in the pediatric population too. There was a paediatric case reported in 2015 of a 6 years old boy with left hemifacial flush and sweating. The ophthalmic and neurological examinations were normal. A MRI of the spine and the brain were performed and showed no lesions. It was the first paediatric idiopathic Harlequin syndrome reported in South Korea (7).

In terms of management of Harlequin syndrome, there are several options of treatment. Sympathectomy or the blocking of the stellate ganglion can be performed. But the results of these surgical procedures are not a hundred percent efficient and can be associated with high risk of perioperative complications (8).

The botulinum toxin injections in the contra-lateral hemiface to block the elevated activity of the sympathetic system, is a therapeutic option too. This procedure was reported as being effective and safe (9).

Surveillance of the syndrome can be proposed and it is the safest therapeutic option. There is a case report in the United Kingdom that showed spontaneous improvement over 3 years of follow up (10).

The medical and surgical options are only required if the patient is in demand of treatment. Psychological and social impacts of this condition should be considered while consulting patients for treatment options.

## CONCLUSION

The Harlequin syndrome is a rare disorder of the sympathetic system of the face. It is a disease that is mostly idiopathic and the mechanism remains unclear till today. Other diseases can cause this disorder and should be ruled out during clinical examination and MRI. There are alternative therapeutics for it but the botulinum toxin injections are the most promising so far with safety and effectiveness. A follow-up should be proposed with significant improvement over the years.

## ACKNOWLEDGMENTS

None.

## AUTHORS' CONTRIBUTIONS

The participation of each author corresponds to the criteria of authorship and contributorship emphasized in the [Recommendations for the Conduct, Reporting, Editing, and Publication of Scholarly work in Medical Journals of](#)

[the International Committee of Medical Journal Editors.](#)

Indeed, all the authors have actively participated in the redaction, the revision of the manuscript, and provided approval for this final revised version.

#### COMPETING INTERESTS

The authors declare no competing interests with this case.

#### PATIENT'S CONSENT

Written informed consents were obtained from the patient for the publication of this case report.

#### REFERENCES

- [1] J. W. Lance, P. D. Drummond, S. C. Gandevia, and J. G. L. Morris, "Harlequin syndrome: the sudden onset of unilateralushing and sweating," *Journal of Neurology, Neurosurgery and Psychiatry*, vol. 51, no. 5, pp. 635–642, 1988.
- [2] Algahtani H, Shirah B, Algahtani R, Alkahtani A. Idiopathic harlequin syndrome manifesting during exercise: a case report and review of the literature. *Case Reports in Medicine*. 2017;5342593:3.
- [3] Khadija Elboukhari, Hanane Baybay, Sara Elloudi et al. Idiopathic harlequin syndrome: a case report and literature review. *Pan African Medical Journal*. 2019;33:141. doi:10.11604/pamj.2019.33.141.18102
- [4] Hans-Bittner NR, Bitner GC, Hans Filho G, "Do you know this syndrome? Harlequin syndrome" *An Bras Dermatol*.2018;93(4):585-6.
- [5] Yeong JJ, Jongbae S, Jong HC, "Harlequin syndrome following resection of mediastinal ganglioneuroma", *Korean J thorac cardiovasc surg* 2017;50:130-132.
- [6] Dong HL, Jong YS, Tae MY, Joon KL, Sang CL, "Harlequin syndrome and Horner syndrome after neck schwannoma excision in a pediatric patient", *Medicine* (2017) 96:45.
- [7] Kim JY, Lee MS, Kim SY, Kim HJ et al, "A pediatric case of idiopathic Harlequin syndrome", *Korean J pediatr* 2016;59(Suppl 1):S125-128.
- [8] H. Reddy, S. Fatah, A. Gulve, and A. J. Carmichael, "Novel management of harlequin syndrome with stellate ganglion block," *British Journal of Dermatology*, vol. 169, no. 4, pp. 954–956, 2013.
- [9] R.K.J.V. Manhaes, M. Spitz and L.F. Vasconcellos, "Botulinum toxin for treatment of Harlequin syndrome," *Parkinsonism and Related Disorders*, vol. 23, pp. 112–113, 2016.
- [10] Emsley HCA, "Postexertional Harlequin syndrome with spontaneous improvement", *BMJ case rep* 2013. doi:10.1136/bcr-2013-200516.