

ORIGINAL RESEARCH

**OCULAR MANIFESTATIONS OF BEHCET'S DISEASE
AN ANALYSIS OF 133 MOROCCAN PATIENTS**

Dr Alami F ; Dr El berdaoui N; Dr Imdary I ; Pr Benchekroun N ; Pr Hajji Z; Pr Berraho A
Department of Ophthalmology A, Rabat Specialties Hospital, Ibn Sina University Hospitals, UM5S, Rabat, Morocco.

Received 15 December, 2013; Revised 16 Mars 2014; Accepted 06 April 2014

ABSTRACT:

Introduction: Behcet's disease is a systemic disorder linked to occlusive vasculitis and of a relatively unknown pathogenesis. Ocular manifestations of the disease mainly comprise uveitis in 60-80% of cases, followed by retinal vasculitis and then retinal vein occlusion. The aim of this study is to analyze ocular manifestations of patients with confirmed Behcet's disease, their complications, treatment and evolution in our tertiary care unit of Morocco.

Patients and methods : It is a retrospective study of patients with confirmed Behcet along with ocular manifestations, hospitalized in the department of ophthalmology at the teaching hospital of Rabat from Juin 2002 to June 2012.

Results: A total of 133 patients were included in the study, being 29,5 years-old on average. Visual acuity is very low before treatment: 56% had less than 1/10. Ocular manifestations included mainly uveitis with 89.96%, followed by retinal vasculitis 73.6% and maculopathy 22%. The percentage of the eyes of which the VA was inferior to 1/10 became 35.9% after the treatment.

Conclusion: The most frequent clinical presentation in our context is a total uveitis with a posterior predominance associated with a vasculitis. Pupillary seclusion is the most frequent complication. Corticotherapy and immunosuppressive drugs are the therapeutic methods used the most in our context.

Key words: Behcet's disease, uveitis, vasculitis, treatment.

Corresponding author:

Dr Fadoua Alami: Department of Ophthalmology A, Rabat Specialities Hospital, Ibn Sina University Hospitals, UM5S, Rabat, Morocco.

Email: alamifadoua@gmail.com

Copyright © 2014 Fadoua Alami et al.

This is an open access article distributed under the [Creative Commons Attribution License](https://creativecommons.org/licenses/by/4.0/), which permits unrestricted use, distribution, and reproduction in any medium, provided the original work is properly cited.

INTRODUCTION

First described in 1937 [1], Behcet's disease is an idiopathic, multisystem inflammatory chronic relapsing disorder, systemic occlusive vasculitis, which affects veins and arteries of all sizes, characterized by recurrent oral aphthous ulcers, genital ulcers, skin lesions, and both anterior and posterior uveitis [2-4]. International Study Group for Behcet's Disease (ICBD) established diagnostic criteria for Behcet's disease; ocular lesions, oral aphthous

ulcerations, and genital aphthous ulcerations are each assigned 2 points, while skin lesions, central nervous system involvement, and vascular manifestations are assigned 1 point each. The pathergy test, when used, was assigned 1 point. A patient scoring ≥ 4 points is classified as having Behcet's disease [5, 6]. Ocular inflammation occurs in approximately 70% of patients and is associated with high risk of blindness [7]. Ocular inflammation as a result of irreversible, progressive, ischemic damage of the retina,

and optic disc, commonly leads to severe panuveitis and its complications [4, 7, 8]. It can be inaugural, habitually bilateral and develops through episodes of remissions [9, 10]. Cataract, secondary glaucoma, optic disc atrophy, and macular edema are the most common complications in Behcet's disease leading to decrease of vision [11, 12]. The aim of this study is to analyze ocular manifestations of patients with confirmed Behcet's disease, their complications, treatment and evolution in our tertiary care unit of Morocco.

MATERIAL AND METHODS

It is a retrospective monocentric study of 133 patients with Behcet's disease, hospitalized in the Department of Ophthalmology in the Teaching Hospital of Rabat between June 2002-2012 and presented with an ocular disease. Only patients whose diagnostic criteria of the International Study Group (ISG) were complete were kept, non-hospitalized and lost to follow-up patients were excluded in our study. "Epi info" was used for the statistical analysis. Information was collected after consent of patient through a prior patient's chart stating the following parameters: age, sex, date of the ocular inflammation onset in relation to the date of behcet's disease diagnosis, ophthalmological signs and data of the initial ophthalmological examination (visual acuity, slit-lamp examination, and fundus photography). All patients have benefitted from: Complete ophthalmic examination; Retinal fluorescein angiography as soon as ocular environments allowed it. +/- Visual field, ERP- ERG, Ocular echography, OCT. Implemented therapeutics was noted as well as the changing profile of the ocular inflammation. Existence of ocular complications was noted. The number of episodes, cause of recurrences and relapses were also reported.

RESULTS

Epidemiology:

Average age at the time of the occurrence of the ocular inflammation in our list is 22.40 years-old +/- 3,2 with extremes between 10 and 54 years-old. Net predominance of males 76.1% (n=101) with a sex ratio of 3.16 ($p < 0,05$). Ocular inflammation reveals the disease in 6.12% of cases (n=8).

Visual acuity:

At the time of diagnosis, 18 patients (6.8% of eyes) were monophthalmus. Initial visual acuity was: $\leq 1/10$ in 56,46% of cases (n=75), between 1- 5/10 in 20,5 % (n=27), and $\geq 5/10$ in 16,3 % (n=21).

Anterior segment inflammation :

Panuveitis is the most frequent inflammation, found in 40.93% (n=54) of patients whereas anterior uveitis was present in only 10.67% (n=14) of cases, among them 4% (n=5) with hypopyon (**Figure 1a, b**). Posterior segment inflammation (**Figure 2a, b, c, d**). Posterior segment inflammation is the most frequent 38.27% (n=50), Intermediate uveitis found in 10.13% (n=13). Retinal vasculitis found in 73.6% (n=97).

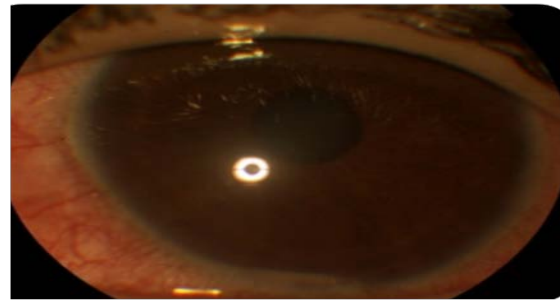


Figure 1a: Behcet's disease: Hypopyon uveitis

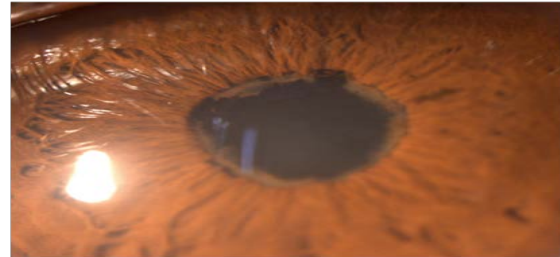

Figure 1b: Behcet's disease: 360° Pupillary seclusion



Figure 2a: Behcet's disease: Fundus photography

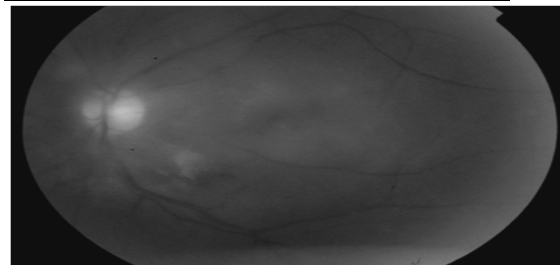


Figure 2b: Behcet's disease: Retinal fluorescein angiography

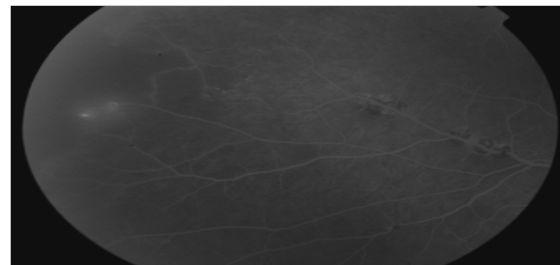


Figure 2c: Behcet's disease: Retinal fluorescein angiography

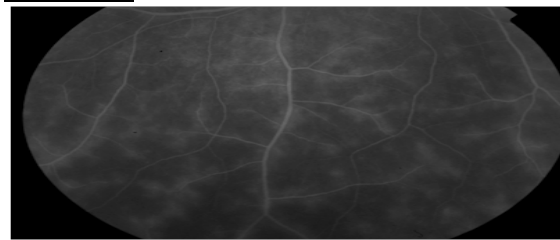


Figure 2d: Behcet's disease: Retinal fluorescein angiography

Complications: (Table 1)

Complications were observed in 43.4% of cases (n=57)

The most frequent ones were:

Macular edema, diffused in 22% of cases (n=29), conditioning the long-term visual prognosis, its diagnosis and supervision relies on the clinical examination, angiography and OCT. Posterior synechias 20% (n=26), with risk of ocular hypertonia. Cataract is less frequent in our list 19% (n=25), usually posterior subcapsular cataract
Optic atrophy and glaucoma in 10% (n=13) of cases.

Type of inflammation	Prevalence (%)
Cataract	19.6
Retinal detachment	4.7
Macular degeneration	18.7
Macular hole	3.7
Pupillary seclusion	20.6
Optic atrophy	6.5
Neovascular glaucoma	4.7
Ocular hypertonia	16.8
Vitreous organization	2.8
Phthisis bulbi	1.9

Table 1: prevalence of the occurrence of main complications.

Treatment:

The deadline to start treatment was one year among more than 7% of our patients (n=93) with an average number of cures of 7.5 during the first year and of an average treatment duration of 4.1 years. Topical mydriatic and cycloplegic treatment to prevent or cure iridocrystalline synechias, and resting the eye.

Corticotherapy given to all patients:

Topical in case of anterior uveitis: Bolus of methylprednisolone (10mg/Kg/day) during three days with a shift by oral route (1mg/Kg/day) with a progressive tapering with a palliation of 10% every 1-2 weeks

Recurrent oral ulceration	Minor aphtous, major aphtous or herpiform ulceration observed by physician or patient, which have recurred at least three times in a 12-month period
And two of the following	
Recurrent genital ulceration	Aphthous ulceration or scarring, observed by physician or patient
Eye lesions	Anterior uveitis, posterior uveitis, or cells in vitreous on slit lamp examination; or retinal vasculitis observed by ophthalmologist
Skin lesions	Erythema nodosum observed by physician or patient, pseudofolliculitis or papulopustular lesions; or acneiform nodules observed by the physician in post-adolescent patients not on corticosteroid treatment
Positive pathergy test	Read by physician at 24-48 hours
The findings are applicable only in the absence of other clinical explanations.	

Table 3 : International study group criteria for the diagnosis of Behcet's disease [5].

Ocular inflammation revealed BD in 6.12% of our cases. In our list, ocular inflammation revealed MB in 8 patients (68 %). In literature, this inflammation can be inaugural in 8-71% of cases [19-21]. There are cases of Behcet's disease without ocular manifestations [4]. Usually, it is initially unilateral. However, bilateralism of lesions seems ineluctable in the absence of treatment and occurs in the first two or three years after the onset of the disease [22].

associated with sodium-restricted and hypocaloric regimen, potassic supplementation, vitamin D and Calcium.

Laterobulbar injection of triamcinolone acetonides: 10 eyes

Sub-Tenons injections of triamcinolone: 3 eyes

Immunosuppressive drugs:

73,45% of patients (n=97) received immunosuppressive drugs: cyclophosphamide: 72,3% (n=96), azathioprine: 1,2% (n=1).

After an average decline of 4.2 years, final visual acuity was <1/10 in 35,9% (n=94) of eyes and ≥ 5/10 in 38,5% (n=102) of eyes (Table 2).

	Initial VA	Final VA
≤1/10	56.5%	35.9%
1/10-5/10	20.5%	21/7%
≥ 5/10	16.3%	38.5%

Table 2 : Evolution of visual acuity

DISCUSSION

Behcet's disease is multisystemic vasculitis, characterized by remissions and exacerbations [6].

Male predominance in our list was not found in others : Male to female ratio was 0.98 in Japan, 0.63 in Korea, 1.19 in Iran, 1.03 in Turkey, and 1.8 in India [4, 13]. We note this net predominance of symptomatic and severe features among males [14-16].

Young patients were the ones affected the most as in our case. The average age found in our study was similar to other reports with 35.7 in Japan, 29 in Korea, 26 in Iran, 25.6 in Turkey, 29 in Greece, 24.5 in Germany, and 24.7 in UK [4, 13].

The severity of the ocular inflammation seems inversely proportional at the age [17]. The incidence of ocular inflammation in Behcet's disease is reported to be 70% [18] and is among the main criteria of Behcet's disease according to ISG (Table 3).

The most frequent clinical presentation in our context is a total uveitis with a posterior predominance associated with a retinal vasculitis, which are consistent with a great number of studies [9, 22, 23].

Our study is consistent with literature concerning the net predominance of this inflammation among young patients, hypopyon frequency and predominance of inflammation of the uveopapillary with periphlebitis (Table 4).

List	Number of eyes	panuveitis	Anterior uveitis	Posterior uveitis	Retinal vasculitis
Janati (20) Maroc	100 eyes	24%	20%	32%	52%
Ouertani Tunisie	246 eyes	72%	-	-	51%
El Belhadji (19) Maroc	832 eyes	37%	30%	45%	32%
Cochereau Massin (21)	56 eyes	-	53%	-	100%
Our study	266 eyes	40,93%	10,67%	38,27%	73,6%

Table 4: Types of ocular inflammations and their frequency according to studies.

Complicated cataract is found in 21-36% of cases according to literature [9]. and 23.6% in our study ; local corticotherapy can favor its evolution and that of inflammatory glaucoma.

Maculopathy is frequent, observed in 16-50% cases according to authors [25-27] and in 31.6% of cases (n=42) in our list, 9.7% (n=13) of macular degeneration and 1.6% (n=2) of macular hole.

Optic nerve inflammation during Behcet's disease is relatively frequent and serious [28], 3.6% of our patients developed optic atrophy. Treatment of ocular inflammatory of Behcet's disease has not been standardized yet. Corticosteroids are commonly used as anti-inflammatory agents for the treatment of the majority of Behcet's disease manifestations. Acute and severe disease exacerbations of anterior (poorly responsive to topical/periorcular corticosteroid) or posterior, or panuveitis as well as retinitis should be treated with higher doses of systemic corticosteroid to offer a rapid response. Oral (prednisolone, 1-2mg/kg/daily or 60-120mg/daily, given in a single morning dose after meals) or intravenous route as pulse methylprednisolone (1 g/daily for three consecutive days) is preferred particularly if bilateral process exists [11, 12, 29]. Numerous authors agree to rapidly use immunosuppressive drugs, either immediately or according to the seriousness or bilaterality of lesions [19].

Cyclosporine A is the most rapidly acting agent for acute uveitis at a daily initial dosage of 5mg/kg, and combined therapy with azathioprine is more effective than monotherapy [12]. Besides systemic cyclosporine A and corticosteroid therapy in treatment of severe forms of uveitis, cytostatic drugs such as azathioprine (50-150mg/daily), methotrexate (7.5- 25mg/week), and colchicine (1-2mg/daily) are effective in controlling the attacks of posterior ocular inflammation and vasculitis, improving the long-term visual prognoses of the disease with prevention of new eye disease [12, 30]. Visual prognostic is conditioned essentially by papillomacular inflammation. Visual loss may also develop as a result of retinal vasculitis and its complications, such as macular edema and others. Typically, patients have episodes of severe uveitis and retinal vasculitis that progressively damaged vision [4]. young age, male sex, and late care are elements of a bad prognosis [9].

In our context, late consultation and therefore a late care of the ocular inflammation worsen the prognosis: 18 eyes (6.8%) had no light perception during the firsts hospitalization. Although we resorted to

immunosuppressive drugs, final visual acuity remained below <1/10 in 35,9 % of cases.

CONCLUSION

Behcet's disease is frequent in Morocco, and is about 24% of all uveitis and 34% of serious uveitis. The most frequent clinical presentation in our context is a total uveitis with a posterior segment predominance associated with a vasculitis. The most frequent complication in our context is Pupillary seclusion. Treatment comprises always corticotherapy and immunosuppressive drugs in 73.45% of cases. Infliximab, anti -TNF- alpha is an advance in the treatment of behcet's disease. Ocular inflammation is severe, requiring a strong collaboration between the ophtalmogist and internist in terms of heavy treatments associating general corticotherapy and immunosuppressive drugs.

ABBREVIATION

ICBD International Study Group for Behcet's Disease
ISG International Study Group

SOURCE OF SUPPORT

Declared none.

COMPETING INTERESTS

The authors declare no competing interests.

AUTHORS' CONTRIBUTIONS

The participation of each author corresponds to the criteria of authorship and contributorship emphasized in the [Recommendations for the Conduct, Reporting, Editing, and Publication of Scholarly work in Medical Journals](#) of the [International Committee of Medical Journal Editors](#). Indeed, all the authors have actively participated in the redaction, the revision of the manuscript and provided approval for this final revised version.

ACKNOWLEDGEMENT

Declared none.

REFERENCES

- [1] H B. Uber rezidivierende aphthose, durch ein virus verursachte geschwure am mund, am auge und an den genitalien. Dermatologische Wochenschrift.36:1152-7.
- [2] Mendes D, Correia M, Barbedo M, Vaio T, Mota M, Gonçalves O, et al. Behçet's disease—a contemporary review. Journal of autoimmunity. 2009;32(3):178-88.

- [3] Pleyer U, Hazirolan D, Winterhalter S, Stübiger N. Behçet's disease-ophthalmological and general aspects part I: etiology, pathogenesis and diagnostics. *Der Ophthalmologe: Zeitschrift der Deutschen Ophthalmologischen Gesellschaft*. 2012;109(11):1129.
- [4] Paovic J, Paovic P, Sredovic V. Behçet's Disease: Systemic and Ocular Manifestations. *BioMed Research International*. 2013;2013:7.
- [5] Davatchi F, Assaad-Khalil S, Calamia K, Crook J, Sadeghi-Abdollahi B, Schirmer M, et al. The International Criteria for Behçet's Disease (ICBD): a collaborative study of 27 countries on the sensitivity and specificity of the new criteria. *Journal of the European Academy of Dermatology and Venereology*. 2013.
- [6] Criteria for diagnosis of Behçet's disease. International Study Group for Behçet's Disease. *Lancet*. 1990;335(8697):1078-80.
- [7] Durrani K, Ahmed M, Foster CS. Adamantiades-Behçet disease: diagnosis and current concepts in management of ocular manifestations. *Comprehensive ophthalmology update*. 2007;8(4):225-33.
- [8] Kitaichi N, Miyazaki A, Iwata D, Ohno S, Stanford MR, Chams H. Ocular features of Behçet's disease: an international collaborative study. *British Journal of Ophthalmology*. 2007;91(12):1579-82.
- [9] Hajji Z, Berraho A. Œil et maladie de Behçet. *EMC Ophtalmologie*. 2003;21-225-C-20.
- [10] Khairallah M, Ben Yahia S, Kahloun R, Khairallah-Ksiaa I, Messaoud R. [The eye and Behçet's disease]. *Journal francais d'ophtalmologie*. 2012;35(10):826-37.
- [11] Stübiger N, Pleyer U. [Typical and atypical ocular manifestations of Behçet's disease]. *Der Ophthalmologe : Zeitschrift der Deutschen Ophthalmologischen Gesellschaft*. 2012;109(6):558-62.
- [12] Paovic J, Paovic P, Sredovic V. Correlation between Ocular Manifestations and Their Complications as Opposed to Visual Acuity and Treatment in Behçet's Disease. *Autoimmune Diseases*. 2013;2013:7.
- [13] Davatchi F, Shahram F, Chams C, Nadji HCA. Behçet's disease. *Acta Medica Iranica*. 2005;43(4).
- [14] Benamour S, Zeroual B, Bennis R, Amraoui A, Bettal S. [Behçet's disease. 316 cases]. *Presse medicale (Paris, France : 1983)*. 1990;19(32):1485-9.
- [15] Ghayad E, Tohme A. [Behçet disease in Lebanon]. *Revue du rhumatisme (Ed française : 1993)*. 1994;61(4):287-8.
- [16] Tugal-Tutkun I, Onal S, Altan-Yaycioglu R, Huseyin Altunbas H, Urgancioglu M. Uveitis in Behçet disease: an analysis of 880 patients. *Am J Ophthalmol*. 2004;138(3):373-80.
- [17] Kone-Paut I. [Behçet's disease: pediatric features]. *Annales de medecine interne*. 1999;150(7):571-5.
- [18] Chiheb S, Chakib A, Lakhdar H. [Behçet's disease]. *Annales de dermatologie et de venerologie*. 2003;130(6-7):657-63.
- [19] Janati K, K ELO, Benchiki H, Hamdani M, Lakhdar H. [Ocular manifestation of Behçet disease (study of 50 patients consulting in dermatology department)]. *La Revue de medecine interne / fondee par la Societe nationale francaise de medecine interne*. 2005;26(10):771-6.
- [20] Filali-Ansary N, Tazi-Mezalek Z, Mohattane A, Adnaoui M, Aouni M, Maaouni A, et al. [Behçet disease. 162 cases]. *Annales de medecine interne*. 1999;150(3):178-88.
- [21] Zierhut M, Saal J, Pleyer U, Kotter I, Durk H, Fierlbeck G. Behçet's disease: epidemiology and eye manifestations in German and Mediterranean patients. *German journal of ophthalmology*. 1995;4(4):246-51.
- [22] el Belhadji M, Hamdani M, Laouissi N, Zaghoul K, Amraoui A, Benamour S. [Ophthalmological involvement in Behçet disease. Apropos of 520 cases]. *Journal francais d'ophtalmologie*. 1997;20(8):592-8.
- [23] Hamza M, Meddeb S, Mili I, Ouertani A. [Bolus of cyclophosphamide and methylprednisolone in uveitis in Behçet's disease. Preliminary results with the use of new criteria of evaluation]. *Annales de medecine interne*. 1992;143(7):438-41.
- [24] Cochereau-Massin I, Wechsler B, Le Hoang P, Le Thi Huong D, Girard B, Rousselle F, et al. [Ocular prognosis in Behçet's disease]. *Journal francais d'ophtalmologie*. 1992;15(5):343-7.
- [25] Atmaca LS. Fundus changes associated with Behçet's disease. *Graefe's archive for clinical and experimental ophthalmology = Albrecht von Graefes Archiv fur klinische und experimentelle Ophthalmologie*. 1989;227(4):340-4.
- [26] Daghfous MT, Ammar M, Kamoun M, Triki F. [Clinical aspects and course of Adamantiades-Behçet disease in Tunisia: a report on 41 cases (author's transl)]. *Journal francais d'ophtalmologie*. 1980;3(8-9):463-8.
- [27] Bencheikroun O, Lahbil D, Lamari H, Rachid R, El Belhadji M, Laouissi N, et al. [Macular damage in Behçet's disease]. *Journal francais d'ophtalmologie*. 2004;27(2):154-9.
- [28] Lamari H, Baha AT, Benhaddou M, Alikane O, Hamdani M, Zaghoul K, et al. [Involvement of the optic nerve in the course of Behçet's disease (presentation of 148 cases)]. *Bulletin de la Societe belge d'ophtalmologie*. 2003(289):9-14.
- [29] Deuter CM, Zierhut M, Doycheva D, Kötter I. [Treatment of Behçet's disease yesterday and today]. *Der Ophthalmologe : Zeitschrift der Deutschen Ophthalmologischen Gesellschaft*. 2012;109(6):568-74.
- [30] Kaklamani VG, Kaklamani PG. Treatment of Behçet's disease—An update. *Seminars in arthritis and rheumatism*. 2001;30(5):299-312.