


2022, Volume 9, ID 598

DOI: [10.15342/ijms.2022.598](https://doi.org/10.15342/ijms.2022.598)

CASE SERIES

True-combined Endodontic - Periodontal Lesion: A Sequential Endodontic Treatment

Salma El abbassi , Bassim Nissrine, Majid Sakout, Faïza Abdallaoui

Department of Endodontics and Restorative Dentistry, Faculty of Dental Medicine, Mohammed V University, Rabat, Morocco.

ABSTRACT

A combined endodontic-periodontal lesion is characterized by the association of endodontic and periodontal infection in the same tooth, attacking and destroying its attachment system. This complicates the therapeutic management because the simultaneous control of the two infections would be inconvenient in clinical practice. It would therefore be essential to sequence the stages of both periodontal and endodontic treatment. The general objective of this article would be to shed light on the contribution of the endodontic approach in the treatment of combined endodontic-periodontal lesions and to specifically underline its influence on the prognosis of this condition.

KEYWORDS: True-combined Endodontic - Periodontal lesion, endodontic treatment.

Correspondence: Dr Salma El abbassi, Address : Department of Endodontics and Restorative Dentistry, Faculty of Dental Medicine, BP: 6212, Rabat instituts, Rabat, Morocco. Email: salmabbss@gmail.com

Copyright © 2022 El abbassi S et al. This is an open access article distributed under the [Creative Commons Attribution 4.0 International](https://creativecommons.org/licenses/by/4.0/), which permits unrestricted use, distribution, and reproduction in any medium, provided the original work is properly cited.

INTRODUCTION

Pulp connective tissue and periodontal tissues come from a common embryological source[1], whose functional specialization is not independent biological structures. On the contrary, they communicate via apical foramen, lateral and accessory canals, and dentinal tubules[2].

The endo-periodontal interconnection allows both physiological and pathological exchange. The influence of pulpal disease on the periodontium no longer needs to be demonstrated. Periodontal suffering can take on multiple aspects: ligament enlargement, bone resorption, condensing osteitis[3]...

However, the influence of periodontal disease on pulp health remains to be qualified. Some authors describe a degenerative reaction in response to stressors of the periodontal pocket, including pulp calcifications and fibrosis[4], while severe pulpal inflammation or total necrosis would be less likely [5]. In summary, unless the loss of attachment extends to the apical or lateral foramen, the dental pulp would be able to defend itself [6].

An endo-periodontal lesion is defined as the coexistence of periodontal and pulpal infection on the same tooth, attacking the attachment system of the tooth. When the pulpal and periodontal pathologies communicate, we can talk about an actual combined endo-periodontal lesion or concomitant lesions.

The actual combined endo-periodontal lesion represents both a diagnostic and a therapeutic challenge because it

involves two biological entities with overlapping clinical and radiological signs.

This article aims to highlight the contribution of the endodontic approach in the context of a true-combined endodontic-periodontal lesion through two clinical cases.

CASE REPORTS

Case 1:

A 21-year-old patient with a non-contributory medical history, followed for generalized aggressive periodontitis (after scaling and root planing), was referred to our department for endodontic treatment on a maxillary left central incisor. At the medical history, the patient described a functional discomfort related to the mobility of the 21; the extra-oral examination was non-contributory; at the visual inspection, we noted the absence of a carie lesion or other hard tissue damage on 21. Tooth 21 was mobile in both directions: vertical and transversal; response to cold test was negative, axial percussion and palpation of the alveolar region of 21 produced mild to moderate pain. Periodontal probing revealed the presence of an attachment loss all around the root periphery. A depth of 10 mm was noted, distal to 21, as the deepest point. Retroalveolar radiography revealed the presence of an apical radiolucency about the root of 21.

A gutta-percha cone was inserted into the periodontal pocket distally to materialize the pocket's pathway; in fact, the radiolucency along the lateral surface of the root was

in continuity with that existing in the apical region. The diagnosis was an actual- combined endodontic-periodontal lesion. The endodontic treatment was administrated in two visits (without any intracanal medication):

We performed a biomechanical preparation at the first appointment using the ProTaper®Gold in combination with irrigation (2.5 % sodium hypochlorite). A temporary coronal filling (IRM®) was placed.

A second appointment was programmed after one week, the tooth was asymptomatic, and the canal was dry without serosities, a canal filling was made by lateral condensation of gutta-percha, followed by a tight and functional coronary restoration (carried out using glass-ionomer cement and micro-hybrid composite)

At three months postoperatively, the 21 regained their physiological mobility, and we noted an amelioration of clinical attachment loss (CAL) (by reducing periodontal probing). At six postoperative months, the retro-alveolar radiography revealed the disappearance of the periapical radiolucency to the root of the 21.

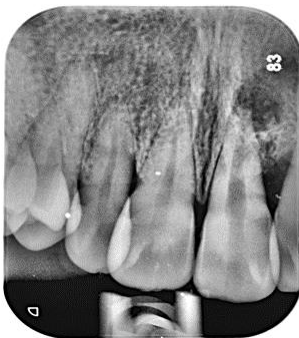

Figure 1: preoperative intraoral radiograph shows a periapical radiolucency related to 21

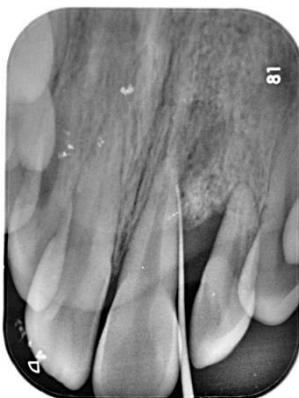

Figure 2: preoperative retro-alveolar radiograph with a gutta-percha cone inserted distally along the loss of attachment

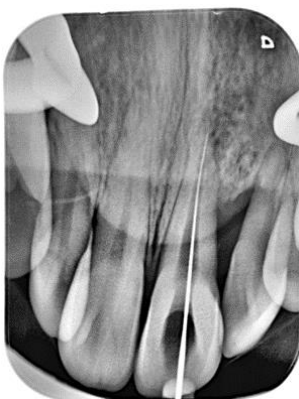

Figure 3 : working length determination

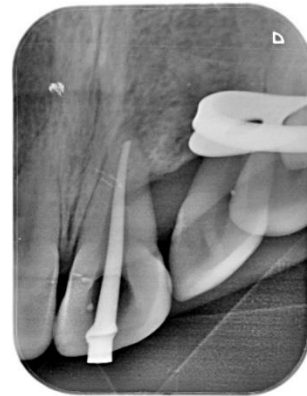

Figure 4 : Master cone

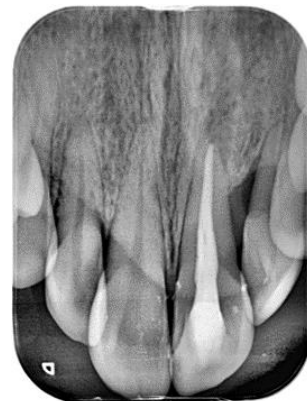

Figure 5 : Postoperative retroalveolar radiograph.

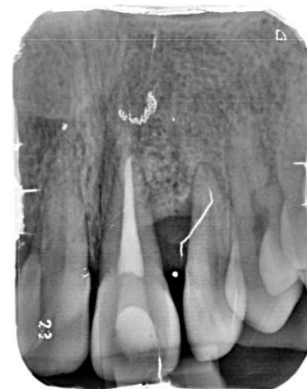

Figure 6: The six-month radiograph recall, showing progressive healing of the bone around the root.

Case 2:

A 25-year-old patient with a non-contributory medical history was referred to our department for a history of spontaneous pain, predominantly at night, related to tooth maxillary left lateral incisor (22). The extraoral examination was non-contributory. The visual inspection revealed an extrusion with a gingival recession (2 mm) on the 22. In the visual inspection, we noted the absence of a carie lesion or other hard tissue damage on 21.

The response to the cold test was negative. The axial percussion and the palpation of the alveolar region produced mild to moderate pain.

Periodontal probing revealed an attachment loss of 8 mm distally.

The preoperative radiography showed a radiolucency image along the distal face of 22 in continuity with that in the periapical region.

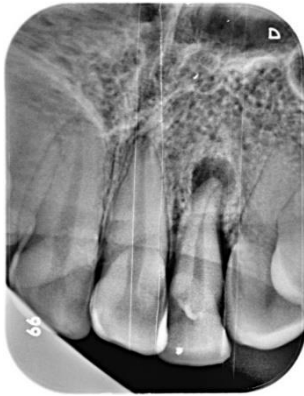

Figure 7: Preoperative intraoral radiograph a periapical radiolucency related to 22

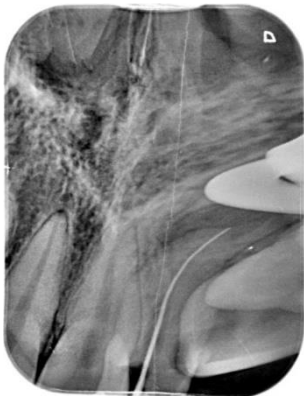


Figure 8 : working length determination

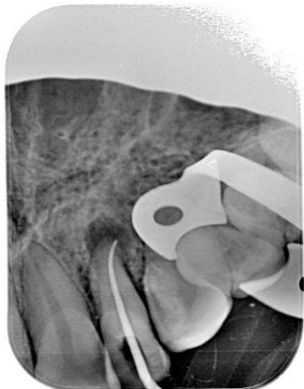

Figure 9: Master cone

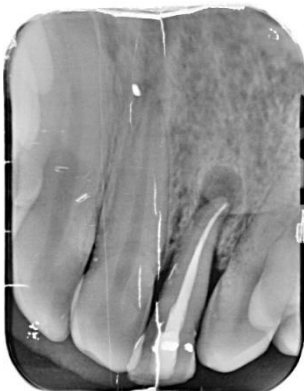


Figure 10: postoperative retroalveolar radiograph.

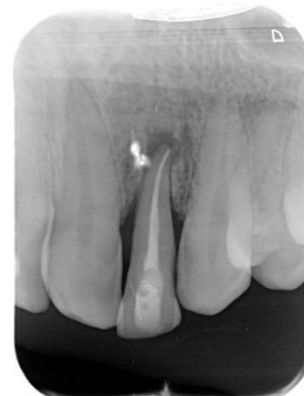

Figure 11: the three-month radiograph recall.

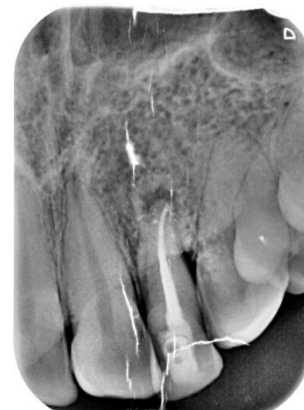

Figure 12 : the six-month radiograph recall, showing progressive healing of the bone around the root.

The diagnosis was a true-combined endodontic-periodontal lesion. After the management of periodontal disease with scaling and root canal planning, and dental patient education, we performed an endodontic treatment in two visits:

After making the access cavity, we performed root canal shaping by the corono-apical technique (using ProTaper®Gold) combined with continuous and abundant irrigation based on sodium hypochlorite (2.5%). A temporary coronal filling (IRM®) was placed.

After one week, the tooth was asymptomatic and the root canal dry (without any interappointment medication). The root canal filling was performed by cold lateral condensation of the gutta-percha, surmounted by a tight and functional coronary filling, using glass-ionomer cement and micro-hybrid composite.

Clinical and radiographic follow-up was instituted at three months, six months, and nine months postoperatively. We noted an amelioration of clinical attachment loss (CAL) by reduction of periodontal probing. The postoperative radiograph at nine months revealed a considerable reduction in the periapical lesion size.

DISCUSSION

Therapeutic Dilemma!

An endo-periodontal lesion implies the coexistence at the same tooth of a lesion of endodontic origin and another periodontal origin; the characteristic: concomitant or independent is based on the histopathological communication or not of the two lesions. The two endodontic and periodontal entities destroy the tooth's attachment system.

Thus, in clinical practice, diagnosing an actual endo-periodontal lesion may seem complicated. Sometimes we could only suppose its existence;

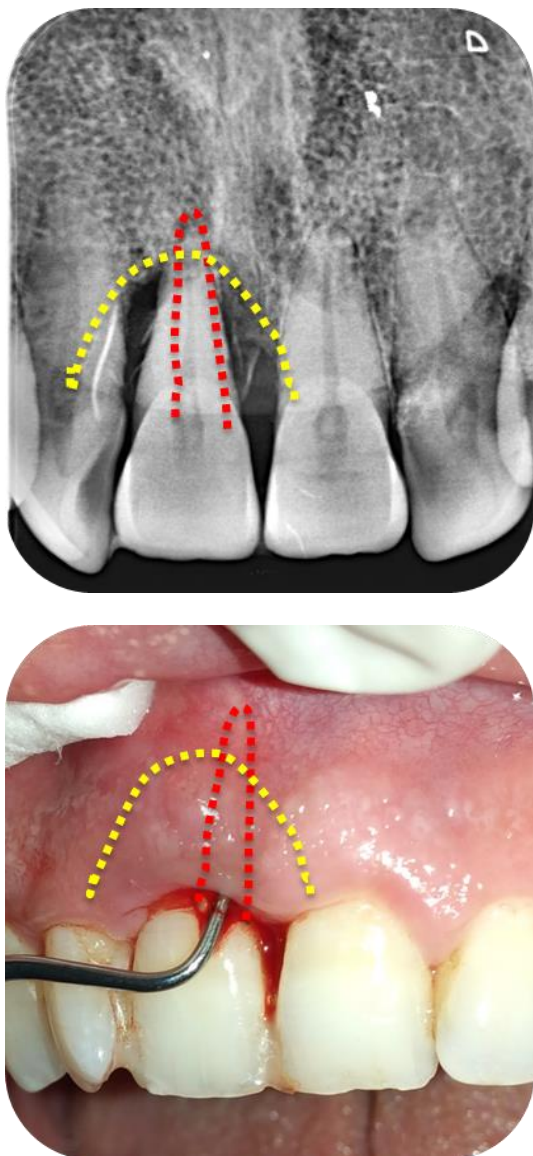


Figure 13 : illustrating the lesional architecture of a true combined endodontic-periodontal lesion: * The red dotted line showing the loss of U-shaped attachment of the endodontic component. * The yellow dotted line showing the loss of V-shaped attachment of the periodontal component.

According to Bonaccorso[7], we can talk about an actual endo-periodontal lesion when there is:

- Susceptibility to the periodontal disease;
- The tooth in question does not respond to pulpal sensitivity tests;
- Periodontal probing shows the architecture of a conical lesion (figure:13) (cervical base and apical point); and another, narrower and more profound, suggesting the presence of desmodontale fistula of endodontic origin. Once the diagnosis has been made, the double origin infectious (endodontic and periodontal bacterial flora) complicates the therapeutic management, indeed some considerations to underline:
 - The periodontal pocket would be a source of pathogens for the endodontic system[8];
 - And continuous cross-seeding of bacteria could occur in either direction[9].

In other words, this possible inter-exchange of pathogens could compromise periodontal treatment if endodontic pathogens are still present. In the opposite direction, bacteria in the periodontal pocket could affect the outcome of the endodontic treatment.

Thus, the two infectious origins must be neutralized simultaneously. This would be difficult in clinical practice. Therefore, it would be essential to sequence the treatment steps reduce the complications of one pathological entity due to the treatment of the other.

At present, there is no consensual clinical protocol on the management of an actual combined endo-periodontal lesion [10,11]. Given the lesional polymorphism, therapeutic decisions would be clinical case-by-case [1].

In the two clinical cases described above, the patients admitted in our department have already benefited from a periodontal treatment (including oral hygiene education, scaling, and root planing).

Subsequently, an endodontic therapy was performed, disinfectant irrigation (based on 2.5% sodium hypochlorite).

Follow-up sessions have been instituted.

We observed a gradual return to physiological mobility during the control visits and a gain of attachment loss. At three months postoperatively, the periapical radiolucency has considerably decreased in volume.

The three-month period was an average waiting period, after which further treatment was decided[12].

Only endodontic treatment favored bone healing in the two clinical cases, which can be seen on control radiographs. Furthermore, the favorable evolution of periodontal parameters (gingival health, periodontal probing) has ruled out the possible recourse to surgical therapy.

In the literature, many authors highlight the importance of controlling endodontic infection in the first place on the prognosis of the actual combined endo-periodontal lesion[7]. Infected root canals provoke an inflammatory response along the root surfaces[14], thus compromising periodontal healing.

In addition, the bone loss induced by endodontic irritants can be resolved by endodontic therapy alone, which is surrounded by bone walls[14]. Moreover, the attachment loss caused by the periodontal pocket infection could be cured by initial periodontal therapy alone[7].

To sum up, the therapeutic strategy for a true combined endodontic-periodontal lesion should firstly be based on optimal canal disinfection followed by the observation of a delay period[15], during which we could observe signs of bone healing that is detected radiographically; after that, the remaining periodontal damage could be treated by a periodontal surgery[10].

CONCLUSION

Trucombined endodontic-periodontal lesions have the worst prognosis; the tissue response to our treatments depends on several parameters[16]: the initial periodontal tissue destruction, the quality of the treatments carried out (endodontic disinfection, oral hygiene education, etc.), patient's compliance and motivation. It can be concluded that there's not only a single prognosis to establish at the start of treatment, but a prognosis to be updated depending on the patient's tissue response after each phase of treatment.

ACKNOWLEDGMENTS

None.

AUTHORS' CONTRIBUTIONS

The participation of each author corresponds to the criteria of authorship and contributorship emphasized in the [Recommendations for the Conduct, Reporting, Editing, and Publication of Scholarly work in Medical Journals of the International Committee of Medical Journal Editors](#). Indeed, all the authors have actively participated in the redaction, the revision of the manuscript, and provided approval for this final revised version.

REFERENCES

- [1] Rotstein I, Simon JH. Diagnosis, prognosis and decision-making in the treatment of combined periodontal-endodontic lesions. *Periodontol* 2000. 2004;34:165-203. DOI: [10.1046/j.0906-6713.2003.003431.x](https://doi.org/10.1046/j.0906-6713.2003.003431.x)
- [2] Rangé H, Les relations complexes entre parodontite et endodontie. *Rev Odont Stomat*. 2007;36:161-178.
- [3] Lasfargues JJ, Machtou P. pathogénèse des lésions périapicales. réalités cliniques. 2001; 12(2):139-148. [Accessed 2021 Dec 27]. Available from: <https://carlgg.files.wordpress.com/2013/07/article-pathogenc3a8se-des-1c3a9sions-pc3a9riapicales.pdf>
- [4] Tan B, Sun Q, Xiao J, Zhang L, Yan F. Pulp status of teeth in patients with chronic advanced periodontitis. *Int J Clin Exp Pathol*. 2020 Apr 1;13(4):635-641.
- [5] Gautam S, Galgali SR, Sheethal HS, Priya NS. Pulpal changes associated with advanced periodontal disease: A histopathological study. *J Oral Maxillofac Pathol*. Jan-Apr 2017; 21(1):58-63. DOI: [10.4103/0973-029x.203795](https://doi.org/10.4103/0973-029x.203795)
- [6] Harrington GW, Steiner DR, Ammons WF. The periodontal-endodontic controversy. *Periodontology* 2000. 2002, 30: 123-130. DOI: [10.1034/j.1600-0757.2002.03012.x](https://doi.org/10.1034/j.1600-0757.2002.03012.x)
- [7] Bonaccorso A, Tripli TR. Endo-perio lesion: diagnosis, prognosis and decision-making. *Endo (lond eng)*. 2014;8(2):105-127. [Accessed 2021 Dec 27]. Available from: http://www.quintpub.com/userhome/endo/endo-ept_8_2_bonaccorso_p105.pdf
- [8] Kerekes K, Olsen I. Similarities in the microfloras of root canals and deep periodontal pockets. *Endod Dent Traumatol*. 1990 Feb;6(1): 1-5. DOI: [10.1111/j.1600-9657.1990.tb00378.x](https://doi.org/10.1111/j.1600-9657.1990.tb00378.x)
- [9] Kipiotti A, Nakou M, Legakis N, Mitsis F. Microbiological findings of infected root canals and adjacent periodontal pockets in teeth with advanced periodontitis. *Oral Surg Oral Med Oral Pathol*. 1984 Aug;58(2):213-220. DOI: [10.1016/0030-4220\(84\)90139-7](https://doi.org/10.1016/0030-4220(84)90139-7)
- [10] Oktawati S, Siswanto H, Mardiana A, Supiaty, Neormansyah I, Basir I. Endodontic-periodontic lesion management: A systematic review, *Medicina Clínica Práctica*. 2020 Jun; 3(1): 2603-9249. DOI: [10.1016/j.mcpsp.2020.100098](https://doi.org/10.1016/j.mcpsp.2020.100098)
- [11] Schmidt JC, Walter C, Amato M, Weiger R. Treatment of periodontal-endodontic lesions—a systematic review. *J Clin Periodontol*. 2014 Aug; 41(8):779-90. DOI: [10.1111/jcpe.12265](https://doi.org/10.1111/jcpe.12265)
- [12] Parolia A, Gail TC, Porto IC, Mala k. Endo-perio lesion: A dilemma from 19 th until 21 st century. *J Interdiscip Dent*. 2013; 3 (1): 2-11. [Accessed 2021 Dec 27]. Available from: <https://www.jidonline.com/text.asp?2013/3/1/2/120514>
- [13] Abbott PV, Salgado JC. Strategies for the endodontic management of concurrent endodontic and periodontal diseases. *Aust Dent J*. 2009 Sep; 54 Suppl 1:S70-85. DOI: [10.1111/j.1834-7819.2009.01145.x](https://doi.org/10.1111/j.1834-7819.2009.01145.x)
- [14] Machtou P, Cohen AG. Diagnostic différentiel des lésions endo-parodontales [Differential diagnosis of endo-periodontal lesions]. *J Parodontol*. 1988 May; 7(2): 155-66.
- [15] Anand V, Govila V, Gulati M. Endo-Perio Lesion: Part II (The Treatment) – A Review. *Arch Dent Sci*. 2012; 3(1):10-16.
- [16] Abbott P. Endodontic management of combined endodontic periodontal lesions. *J N Z Soc Periodontol*. 1998;(83):15-28.

COMPETING INTERESTS

The authors declare no competing interests with this case.

FUNDING SOURCES

None.

PATIENTS CONSENT

Written informed consents were obtained from the patients for the publication of this article.