




2024, Volume 11, ID 735

DOI: [10.15342/ijms.2024.735](https://doi.org/10.15342/ijms.2024.735)

## CASE REPORT

# A Case of Penile Necrosis in a Patient with Simultaneous Fournier's Gangrene and Priapism

Zakaria Bakali Issaoui , Ayoub Gaudan, Youssef Kharbach , Abdelhak Khallouk 

Department of Urology, Mohammed VI University Hospital  
Faculty of Medicine and Pharmacy, Abdelmalek Essaâdi University, 90000 Tangier, Morocco

### ABSTRACT

Fournier's gangrene (FG) is a necrotizing fasciitis of the perineal and genital areas, characterized by severe complications and a high level of mortality. The occurrence of concurrent priapism is extremely rare and carries a very poor prognosis. Here, we report a case of a 74-year-old male patient with no medical history who presented with FG of the scrotum and penis associated with simultaneous priapism. He was given intravenous antibiotic therapy, cavernous aspiration, and surgical debridement. In the following days, the penis became completely necrotic. A total penectomy was performed with a perineal urethrostomy following complete wound closure. There are only a few documented cases in the medical literature of simultaneous Fournier's gangrene and priapism. As a result, there is no established protocol for managing this rare occurrence. When gangrene extends to the penis, cavernous aspiration is not recommended as it tends to exacerbate penile necrosis in the majority of cases. However, early administration of broad-spectrum antibiotic therapy, surgical debridement, and urinary diversion are necessary to prevent necrosis and sepsis.

**Keywords:** Fournier's Gangrene; Priapism; Penile Necrosis; Total Penectomy.

**Correspondence:** Dr. Bakali Issaoui Zakaria, Department of Urology, Mohammed VI University Hospital, Faculty of Medicine and Pharmacy, Abdelmalek Essaâdi University, 90000 Tangier, Morocco. Email: [Zakariaissaoui753@gmail.com](mailto:Zakariaissaoui753@gmail.com)

**Copyright © 2024 Bakali Issaoui Z et al.** This is an open access article distributed under the [Creative Commons Attribution 4.0 International](https://creativecommons.org/licenses/by/4.0/), which permits unrestricted use, distribution, and reproduction in any medium, provided the original work is properly cited.

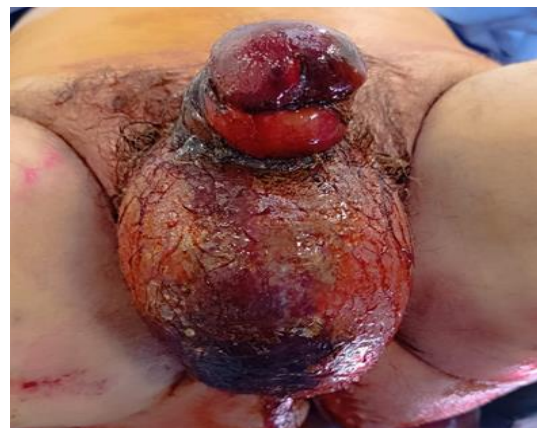### INTRODUCTION

Fournier's gangrene (FG) is a rare but severe necrotizing fasciitis, with an incidence rate of 1.6 cases per 100,000 males per year [1,2]. It is a polymicrobial infection that most frequently occurs in patients with risk factors such as diabetes and chronic kidney disease. The etiology is identified in 95% of cases [3]. This medical emergency can result in sepsis and death. We present the case of a 74-year-old patient with no significant past medical history who developed FG and priapism, leading to complete necrosis of the penis.

### CASE REPORT

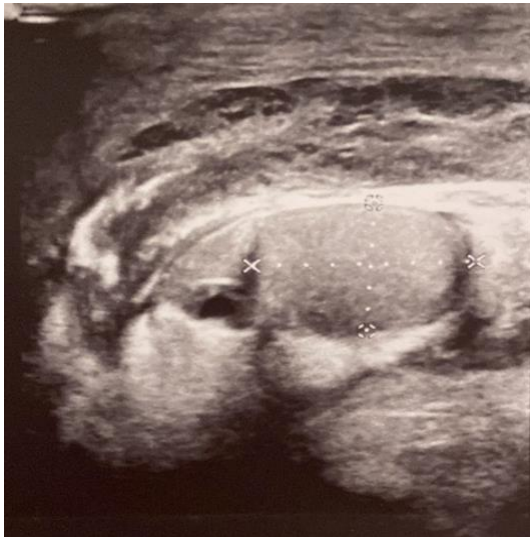A 74-year-old patient was admitted to the emergency department with large painful, inflamed bursae and penis. The initial symptoms manifested one month ago with erythematous lesions on the bursae. These lesions spread to the penis and thighs. The patient had a history of tinea cruris untreated. He had no toxic habits and no history of diabetes, chronic renal disease, or recent trauma. Clinical examination revealed

wet gangrene of the bursae with a 4 cm area of necrosis and subcutaneous crepitus, a hard, swollen penis associated with an ischemia-related hemorrhagic mucosal suffusion, and tinea cruris (Fig. 1).



**Fig 1:** Fournier's gangrene associated with priapism.

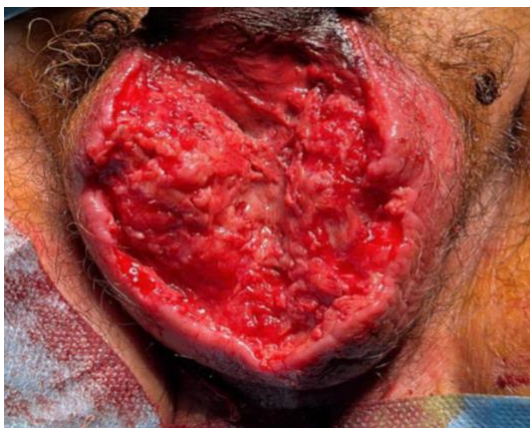Moreover, the rectal examination was normal. Vital signs were as follows: blood pressure, 120/80 mmHg; pulse, 95 bpm; body temperature, 36.5°C; respiration rate, 20. Laboratory tests showed the following: hemoglobin, 9.5 mg/dl; leukocyte, 19000/uL; C-reactive protein, 506 mg/dl; thrombocyte, 134000/uL; creatinine, 26 mg/l; sodium, 145 mmol/L; potassium, 4.7 mmol/L; glucose, 160 mg/dl; HbA1c value, 4.8%. Urine tests were negative results, as well as the HIV test. Scrotal and perineal ultrasonography revealed a thickening of the scrotal wall and a subcutaneous emphysema (Fig. 2). Color Doppler revealed a decreased flow in the cavernosal arteries.



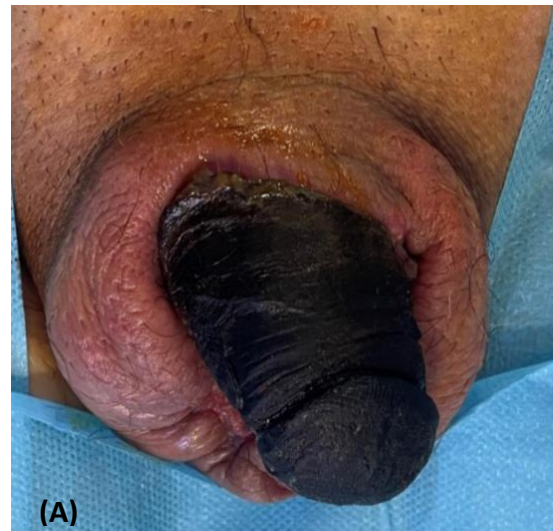**Fig 2:** Scrotal US: thickening of the scrotal wall and subcutaneous emphysema.

Broad-spectrum antibiotic treatment was immediately initiated, combining imipenem and metronidazole. A suprapubic catheter was performed. Surgical exploration revealed scrotal necrosis. We performed a complete necrosectomy and considered the penile induration as an associated priapism. We also performed a cavernous aspiration, which revealed black blood (Fig. 3).

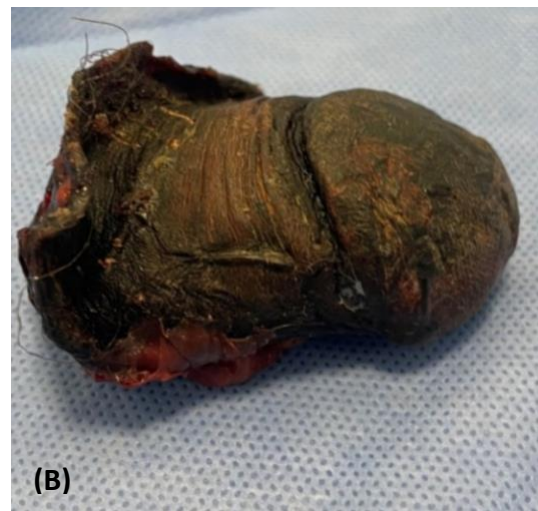Furthermore, after 20 days, we decided to perform a complete penectomy with a perineal urethrostomy for urine diversion (Fig. 5). He continued to have appointments with a psychologist both during and after his hospital stay to address the psychological effects of his condition.



**Fig 3:** Aspect after Surgical debridement of necrotic tissue.

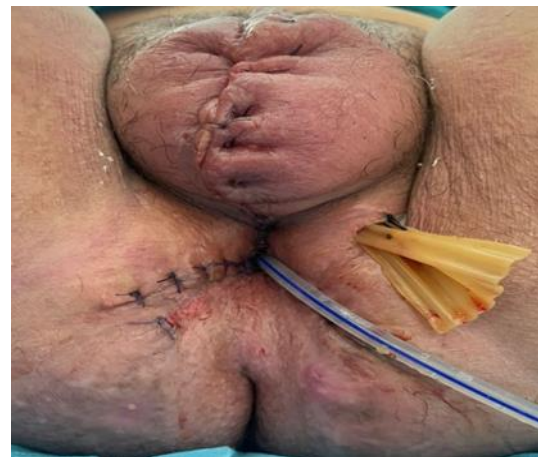

(A)



(B)

**Fig 4:** (A) complete penile necrosis. (B) Pathology specimen (Total penectomy).



**Fig 5:** Aspect after Perineal urethrostomy.

## DISCUSSION

FG is a polymicrobial type I necrotizing fasciitis of the perineal, perianal, or genital areas, with severe complications and a high level of mortality. It is characterized by obliterative endarteritis of the subcutaneous arteries, leading to gangrene of the skin and subcutaneous tissue [4]. A simultaneous priapism is very rare; it has two primary mechanisms: high-flow priapism,



which is commonly associated with a penile or perineal trauma; low-flow or ischemic priapism, which is more frequent and arises from vascular stagnation and decreased venous drainage [5]. In our case, it was most likely attributed to a low-flow mechanism resulting from thrombosis of corporeal sinusoidal spaces and draining veins secondary to the infectious process.

FG can impact individuals of various ages and genders; it predominantly affects men aged between 30 and 60 [6]. It has been shown to be associated with many conditions such as diabetes mellitus, alcoholism, atherosclerosis, immunosuppression, local trauma, genitourinary infections [7], and liver or renal disease [8]. It is rarely truly idiopathic, an identifiable cause in approximately 95% of cases; it frequently stems from urethral, anorectal, and skin infections [9].

By definition, FG is a polymicrobial infection; both anaerobic and aerobic organisms can be involved [10]. The clinical examination of our patient revealed a tinea cruris with fissuring of the inguinal folds, which may be a potential portal of entry. We found *Klebsiella pneumoniae* in the skin culture. The pus culture was polymicrobial.

The diagnosis of FG is mainly clinical, with the most frequent symptoms being scrotal pain and swelling, erythema, and fever. Clinical examination of the perineum and genitalia may reveal subcutaneous crepitus, tissue necrosis, and pus. The disease is often silent and has a painless onset, which can delay the diagnosis [11]. Radiological investigations and laboratory tests are crucial if the diagnosis is uncertain. However, definitive diagnosis is usually based on surgical exploration. Laboratory findings are not specific, and the most commonly observed are elevated serum creatinine, leukocytosis, anemia hyponatremia, hypocalcemia, and hyperglycemia [12-15]. Scrotal and perineal ultrasonography may reveal thickening of the scrotal wall and subcutaneous emphysema, which appears as echogenic zones showing reverberation artifact with the classical "dirty" shadowing [16]. CT is very useful for identifying the source of infection and evaluating the extent of the necrosis. It may uncover subcutaneous emphysema, soft tissue inflammation, and thickening [16]. Limited cases in the literature discuss the utilization of MRI in FG, as it can reveal the same abnormalities observed in CT. Moreover, due to its wider field of view, MRI enables a thorough evaluation of the infection's extent, which is particularly advantageous in cases of advanced lesions [9]. The diagnosis in our case was obvious from the necrosis of the scrotal wall and the subcutaneous crepitus. The US confirmed the diagnosis, showing subcutaneous emphysema. Surgical exploration revealed a more extensive necrosis that was observed clinically.

Treatment in FG aims to halt the spread of infection and necrosis and to avoid sepsis and systemic toxicity. Treatment includes intensive fluid resuscitation, correction of electrolyte imbalance, broad-spectrum antibiotic therapy, and early surgical debridement [17]. FG is a polymicrobial infection; hence, a broad-spectrum antibiotic is necessary. At present, no specific recommendations exist regarding the optimal antibiotic therapy. Generally, triple therapy with penicillin, metronidazole, and third-generation cephalosporins with aminoglycosides is essential [18]. Nonetheless, surgical exploration is imperative to judge the extent of the

infection. Early and radical debridement of devitalized tissue is the crucial step in stopping the infection's progression and is the most essential for survival [19]. The urinary diversion continues to be a subject of debate. Some authors advocated for urinary diversion in all cases (through a suprapubic cystostomy). Conversely, others suggested that urinary diversion should be performed only for patients with extensive urethral inflammation [20]. The suprapubic cystostomy was necessary for our patient due to periureteral inflammation. Several researchers recommended using hyperbaric oxygen therapy (HBOT) as it increases tissue viability and growth and it is initiated after patient stabilization and is sustained until wound closure is achieved [21,22].

The occurrence of priapism was a notable feature in our case. As the duration of our patient's priapism exceeded 24 hours, we decided to treat it according to the isolated priapism protocol, but unfortunately, cavernous aspiration was unsuccessful. A similar case was published by Charbonneau, H., and Pène, F, in 2010 of crackling priapism related to FG5, where irrigation of corpora cavernosa and penile shunt was unsuccessful. The management of FG associated with priapism is challenging. Penile aspiration in a septic environment may lead to the introduction of the germ into the deep tissues of the penis at the level of the sinusoidal cavities of the corpora cavernosa, which may explain the rapid worsening of the necrosis, ultimately leading to the total necrosis of the penis. Cavernous aspiration must be reconsidered, as it may aggravate the infection and accelerate penile necrosis. Clinical differentiation between dry and wet gangrene is decisive when choosing the appropriate treatment. In cases of dry gangrene, the two treatment strategies include conservative treatment and partial penectomy [23]. Wet gangrene generally requires more aggressive treatment, usually with a complete penectomy. In our patient, we decided to be conservative at first until the constitution of the penile necrosis. Perineal urethrostomy for urine diversion was necessary once complete wound healing had occurred.

## CONCLUSION

FG is a serious and fatal condition that, despite prompt and appropriate treatment, carries a poor prognosis. The simultaneous occurrence of GF and priapism is exceptionally rare, and the resulting infection is associated with a more severe clinical course. Cavernous aspiration must be carefully considered and may aggravate necrosis. Antibiotic therapy is the mainstay of treatment. It is necessary to perform prompt, extensive debridement surgery with a complete penectomy to prevent the spread of infection and sepsis. Following complete wound closure, a definitive urinary diversion is required.

## ACKNOWLEDGMENTS

The authors like to express their gratitude to the patient from whom they have gained valuable knowledge.

## CONFLICTS OF INTEREST

The authors declare no conflicts of interest in this case.

## AUTHORS' CONTRIBUTIONS

The participation of each author corresponds to the criteria of authorship and contributorship emphasized in the

[Recommendations for the Conduct, Reporting, Editing, and Publication of Scholarly Work in Medical Journals of the International Committee of Medical Journal Editors.](#) Indeed, all the authors have actively participated in the

redaction and revision of the manuscript and provided approval for this final revised version.

## REFERENCES

- [1] Chernyadyev SA, Ufimtseva MA, Vishnevskaya IF, Bochkarev YM, Ushakov AA, Beresneva TA, et al. Fournier's Gangrene: Literature Review and Clinical Cases. *Urol Int.* 2018;101(1):91-97. DOI: [10.1159/000490108](https://doi.org/10.1159/000490108)
- [2] Sorensen MD, Krieger JN. Fournier's Gangrene: Epidemiology and Outcomes in the General US Population. *Urol Int.* 2016;97(3):249-259. DOI: [10.1159/000445695](https://doi.org/10.1159/000445695)
- [3] Singh V, Sinha RJ, Sankhwar SN. Penile gangrene: a devastating and lethal entity. *Saudi J Kidney Dis Transplant Off Publ Saudi Cent Organ Transplant Saudi Arab.* 2011;22(2):359-361.
- [4] Korkut M, İçöz G, Dayangaç M, Akgün E, Yeniay L, Erdoğan O, et al. Outcome analysis in patients with Fournier's gangrene: report of 45 cases. *Dis Colon Rectum.* 2003 May;46(5):649-52. DOI: [10.1007/s10350-004-6626-x](https://doi.org/10.1007/s10350-004-6626-x)
- [5] Charbonneau H, Pène F. A crackling priapism related to Fournier's gangrene in a patient on chronic peritoneal dialysis. *J Infect.* 2010;61(3):274-275. DOI: [10.1016/j.jinf.2010.06.011](https://doi.org/10.1016/j.jinf.2010.06.011)
- [6] Kuchinka J, Matykiewicz J, Wawrzycka I, Kot M, Karcz W, Głuszek S. Fournier's gangrene - challenge for surgeon. *Pol Przegl Chir.* 2019;92(5):1-5. DOI: [10.5604/01.3001.0013.5894](https://doi.org/10.5604/01.3001.0013.5894)
- [7] Morpurgo E, Galandiuk S. Fournier's gangrene. *Surg Clin North Am.* 2002 Dec;82(6):1213-24. DOI: [10.1016/s0039-6109\(02\)00058-0](https://doi.org/10.1016/s0039-6109(02)00058-0)
- [8] Dey S, Bhutia KL, Baruah AK, Kharga B, Mohanta PK, Singh VK. Neonatal Fournier's gangrene. *Arch Iran Med.* 2010;13(4):360-362.
- [9] Cakmak A, Genç V, Akyol C, Kayaoğlu HA, Hazinedaroğlu SM. Fournier's gangrene: is it scrotal gangrene? *Adv Ther.* 2008;25(10):1065-1074. DOI: [10.1007/s12325-008-0103-1](https://doi.org/10.1007/s12325-008-0103-1)
- [10] Morua AG, Lopez JAA, Garcia JDG, Montelongo RM, Guerra LSG. Fournier's gangrene: our experience in 5 years, bibliographic review and assessment of the Fournier's gangrene severity index. *Arch Esp Urol.* 2009;62(7):532-540.
- [11] Tahmaz L, Erdemir F, Kibar Y, Cosar A, Yalcın O. Fournier's gangrene: report of thirty-three cases and a review of the literature. *Int J Urol.* 2006 Jul;13(7):960-7. DOI: [10.1111/j.1442-2042.2006.01448.x](https://doi.org/10.1111/j.1442-2042.2006.01448.x)
- [12] Koukouras D, Kallidonis P, Panagopoulos C, Al-Aown A, Athanasopoulos A, Rigopoulos C, et al. Fournier's gangrene, a urologic and surgical emergency: presentation of a multi-institutional experience with 45 cases. DOI: [10.1159/000321691](https://doi.org/10.1159/000321691)
- [13] Villanueva-Sáenz E, Martínez Hernández-Magro P, Valdés Ovalle M, Montes Vega J, Alvarez-Tostado F JF. Experience in management of Fournier's gangrene. *Tech Coloproctology.* 2002;6(1):5-10; discussion 11-13. DOI: [10.1007/s101510200001](https://doi.org/10.1007/s101510200001)
- [14] Hosseini SJ, Rahmani M, Razzaghi M, Barghi M, Hosseini Moghaddam SMM. Fournier gangrene: a series of 12 patients. *Urol J.* 2006;3(3):165-170.
- [15] Schaeffer A. Infections of the Urinary Tract. In: Walsh P, Retik A, Vaughan E, Wein A, eds. *Campbell's Urology, Eighth Edition.* Saunders; 2002:515-602.
- [16] Gupta N, Zinn KM, Bansal I, Weinstein R. Fournier's gangrene: ultrasound or computed tomography? *Med Ultrason.* 2014;16(4):389-390.
- [17] Singh A, Ahmed K, Aydin A, Khan MS, Dasgupta P. Fournier's gangrene. A clinical review. *Arch Ital Urol Androl Organo Uff Soc Ital Ecogr Urol E Nefrol.* 2016;88(3):157-164. DOI: [10.4081/aiua.2016.3.157](https://doi.org/10.4081/aiua.2016.3.157)
- [18] Hejase MJ, Simonin JE, Bihrlé R, Coogan CL. Genital Fournier's gangrene: experience with 38 patients. *Urology.* 1996;47(5):734-739. DOI: [10.1016/s0090-4295\(96\)80017-3](https://doi.org/10.1016/s0090-4295(96)80017-3)
- [19] Thwaini A, Khan A, Malik A, et al. Fournier's gangrene and its emergency management. *Postgrad Med J.* 2006;82(970):516-519. DOI: [10.1136/pgmj.2005.042069](https://doi.org/10.1136/pgmj.2005.042069)
- [20] Jones RB, Hirschmann JV, Brown GS, Tremann JA. Fournier's syndrome: necrotizing subcutaneous infection of the male genitalia. *J Urol.* 1979;122(3):279-282. DOI: [10.1016/s0022-5347\(17\)56367-3](https://doi.org/10.1016/s0022-5347(17)56367-3)
- [21] Kindwall EP. Uses of hyperbaric oxygen therapy in the 1990s. *Cleve Clin J Med.* 1992;59(5):517-528. DOI: [10.3949/ccjm.59.5.517](https://doi.org/10.3949/ccjm.59.5.517)
- [22] Capelli-Schellpfeffer M, Gerber GS. The use of hyperbaric oxygen in urology. *J Urol.* 1999;162(3 Pt 1):647-654. DOI: [10.1097/00005392-199909010-00002](https://doi.org/10.1097/00005392-199909010-00002)
- [23] Gillitzer R, Franzaring L, Hampel C, Pahernik S, Bittinger F, Thüroff JW. Complete gangrene of penis in patient with arterial vascular disease. *Urology.* 2004;64(6):1231.e4-6. DOI: [10.1016/j.urology.2004.06.004](https://doi.org/10.1016/j.urology.2004.06.004)