


CASE REPORT

**A RARE PRESENTATION OF BILATERAL VOCAL
CORD PARALYSIS IN LATE STAGE PARKINSON'S
DISEASE**

Sharir Asrul Bin ASNAWI¹ , Mohd Hazmi Bin MOHAMED², Mohamad Bin DOI³

Universiti Kebangsaan Malaysia Medical Centre (UKMMC) 
Universiti Putra Malaysia

ABSTRACT

Introduction: Vocal cord paralysis often causes mortality by upper airway obstruction in some neurodegenerative diseases such as Parkinson's disease and multiple system atrophy. Vocal cord paralysis is uncommon in Parkinson's disease (PD) in contrary it is more common in multiple system atrophy (MSA). The pathogenesis of vocal cord paralysis in Parkinson's disease is not well understood but may involve degeneration of the nucleus ambiguus. In terms of managing patient with bilateral vocal cord paralysis in PD, it can be either performing tracheostomy to relieve the upper airway obstruction or by optimizing the medical treatment. There are very few available reported cases whereby patient are treated with medical treatment alone.

Case Report: We report a case of 65 years old lady who presented with stridor resulting from bilateral vocal cord paralysis and she has been diagnosed to have Parkinson's disease for more than 10 years. She had her antiparkinson medication optimized and requiring no surgical intervention to relieve the upper airway obstruction.

Conclusion: In conclusion we would like to emphasize that it is important to recognize bilateral vocal cord paralysis in Parkinson's disease and early optimization of medical treatment could avoid a need of tracheostomy.

KEY WORDS: Stridor, Vocal Cord Paralysis, Late Stage Parkinson's Disease, Upper Airway Obstruction.

Corresponding author: Dr Sharir Asrul Asnawi, Department of ORL, Head & Neck Surgery, Universiti Kebangsaan Malaysia Medical Centre, Jalan Ya'acob Latif, Bandar Tun Razak, 56000 Cheras, Kuala Lumpur, Malaysia
Phone number: +60196897721 Fax Number: +603 9145 6675 E-mail: sharirasrul@gmail.com

Copyright © 2018 Asrul Asnawi Sharir et al.

This is an open access article distributed under the [Creative Commons Attribution 4.0 International](https://creativecommons.org/licenses/by/4.0/), which permits unrestricted use, distribution, and reproduction in any medium, provided the original work is properly cited.

INTRODUCTION

Parkinson's disease (PD) is one of the most common neurologic disorder affecting approximately 1% of individuals older than 60 years. The incidence of Parkinson's disease is 4.5-21 cases per 100,000 population per year. [1] PD is characterized by rigidity, tremor, bradykinesia, speech impairment and a gait disorder. The histopathologic hallmark of the disease is degeneration of the pigmented neurons in substantia nigra.

Vocal cord paralysis often causes mortality by upper airway obstruction in some neurodegenerative diseases such as Parkinson's disease and multiple system atrophy. [2] Vocal cord paralysis is rare in Parkinson's disease (PD) in contrary it is more common in multiple system atrophy (MSA). To the best of our knowledge there are few cases reported in English journal as an example Chia Chan Tsai et al. [3] reported one patient with bilateral vocal cord paralysis in PD, Plasse et al. [4] reported 2 cases and Isozaki et al. [5] reported 3 cases.

In this article we report one rare case of bilateral vocal cord abductor paralysis in late stage Parkinson's disease. The case was unique in the sense that some of the available literature reported that patient end up having tracheostomy as a treatment for upper airway obstruction secondary to bilateral vocal cord abductor paralysis however we observed that tracheostomy can be avoided if prompt recognition of this condition and immediate medical treatment being optimized.

CASE REPORT

A 65 years old lady who has been diagnosed to have Parkinson's disease (PD) stage 5 presented with stridor for 1 week. She has been treated for Parkinson's disease for more than 10 years on which her earlier presentation was tremor, rigidity and bradykinesia. Her disability due to PD eventually reached stage 5 based on Hoehn and Yahr scale in the last 4 years whereby patient is bed ridden which necessitate Ryle's tube feeding. She was admitted multiple times for bronchopneumonia. One week prior to hospitalization she presented with stridor which was aggravated by her tremors and bradykinesia. Her stridor reduces when she sleeps or when her tremor decrease. There was no history of thyroid disease, diabetes, smoking or alcohol intake.

On examination she is bed ridden, presence of severe bradykinesia, tremor and severe rigidity. There is inspiratory stridor. No anterior neck mass on examination. Indirect laryngoscope (Fig. 1, 2) showed vocal cord in paramedian position with collection of secretion. Her laryngeal sensation is also reduced. The results of laboratory test was noncontributory. Chest x-ray were unremarkable with normal mediastinum.

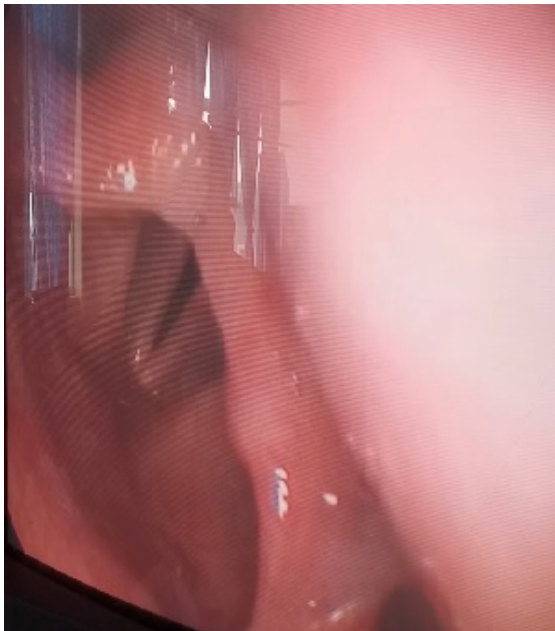

Figure 1: indirect laryngoscope during inspiratory phase shows narrowing of rima glottides.

Her antiparkinsonism medication was optimized by neuromedical team and she was observe closely in the ward for more than a week. Patient oxygen saturation was monitored continuously whereby it was not less than 95%

under room air. Clinically her inspiratory stridor was observed to be heavy when her tremor worsen but there was no desaturation less than 95%. During her hospitalization her antiparkinsonism medication was adjusted diligently that we observe she has less tremor, rigidity and dyskinesia which less aggravating her stridor. Another repeated indirect laryngoscope (Fig. 1, 2) was performed which shows similar finding as earlier scope. She was subsequently discharge home with a regular follow up.

DISCUSSION

Upper airway obstruction secondary to bilateral vocal cord paralysis in Parkinson's disease is uncommon. It is more frequently seen in Multiple System Atrophy. In Huppler et al. series, only two out of 633 with unilateral and bilateral vocal cord paralysis had Parkinsonism. [6] Holinger et al. also found a low incidence with only four Parkinson's patient out of 389 patients with partial or complete bilateral vocal cord paralysis. [7]

Laryngeal and esophageal musculature are influenced by the nucleus ambiguus. They are controlled by basal ganglia and its descending fibers in the vagus nerve. The pathogenesis of vocal cord paralysis in Parkinson's disease is not well understood but may involve degeneration of the nucleus ambiguus which has been demonstrated in cadaveric studies in patient in patient with multiple system atrophy. [5] Multiple system atrophy is a neuro degenerative disease characterized by varying degrees of Parkinsonism, and cerebellar and autonomic dysfunction. [8] Liberman et al. postulated the mechanism if vocal cord paralysis in patient with parkinson's disease and multiple system atrophy is similar. [2]

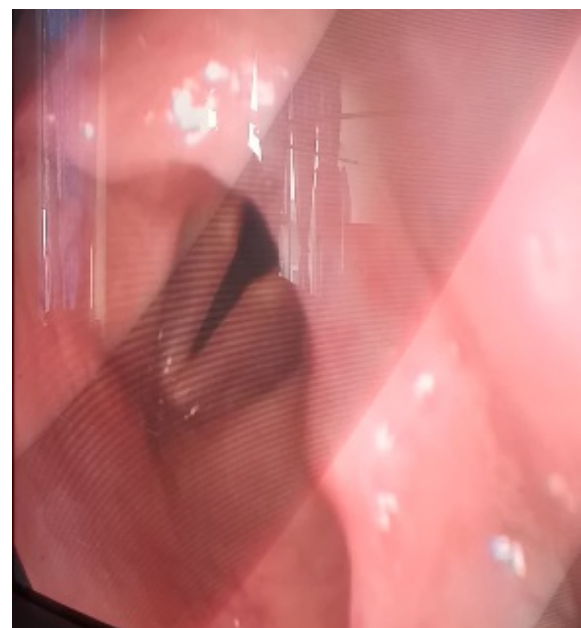


Figure 2: indirect laryngoscope during expiratory phase shows paradoxical movement.

Isozaki et al. reported some of the disparity of vocal cord palsy between PD and MSA; (1) clinical laryngoscopy examination showed that VCAP in PD was not

exacerbated during sleep unlike in MSA; (2) on histological examination of the intrinsic laryngeal muscles, the posterior cricoarytenoid muscle demonstrated no abnormalities in PD, while in MSA it showed neurogenic atrophy. (3) Severe dysphagia requiring tube feeding was common among PD patients as compared to MSA patients. [5]

In terms of managing patient with bilateral vocal cord paralysis in PD, it can be either performing tracheostomy to relieve the upper airway obstruction as reported by Vas et al. [9], Plasse & Lieberman [4], Read & Young [10], Corbin & Williams [11], Lew et al. [12], Nakane et al. [13], Onoue et al. [14], Qayyum et al. [15] or by optimizing the medical treatment. There are very few available reported cases whereby patient are treated with medical treatment alone ie reported by Chia et al. [3] and Corbin & Williams [11].

AUTHORS' CONTRIBUTIONS

The participation of each author corresponds to the criteria of authorship and contributorship emphasized in the [Recommendations for the Conduct, Reporting, Editing, and Publication of Scholarly work in Medical Journals](#) of the [International Committee of Medical Journal Editors](#). Indeed, all the authors have actively participated in the redaction, the revision of the manuscript and provided approval for this final revised version.

REFERENCES

- [1] Muangpaisan W; Mathews A; Hori H; Seidel D. A systemic Review of the Worldwide prevalence and incidence of Parkinson's disease. *J Med Assoc Thai.* 2011; 94(6):749-55.
- [2] Lieberman AN. Parkinson's disease: A Clinical Review. *Am J Med Sci* 1974; 267:66-80.
- [3] Chia Chan Tsai; Meng Ni Wu; Li Min Liou. Levodopa reverse stridor and prevent subsequent endotracheal intubation in Parkinson disease patients with bilateral vocal cord palsy. *Medicine (Baltimore).* 2016 Dec; 95(50):e5559.
- [4] Plasse HM; Lieberman AN. Bilateral vocal cord paralysis in Parkinson's disease. *Arch Otolaryngol.* 1981 Apr; 107(4):252-3.
- [5] Isozaki E; Naito R; Kanda T; Mizutani T; Hirai S. Different mechanism of vocal cord paralysis between spinocerebellar ataxia and multiple system atrophy. *J Neurol Sci* 2002 May 15;197(1-2):37-43.
- [6] Huppler EG, Schmidt HW, Devine D, Gage RP. Causes of vocal cord paralysis. *Mayo Clin Proc* 1955;30:518-21
- [7] Holinger LD, Holinger PC, Holinger PH. Etiology of bilateral vocal cord paralysis: a review of 389 cases. *Ann Otol Rhinol Laryngol* 1976;85:428-36
- [8] Blumin JH, Berke GS. Bilateral vocal fold paresis and multiple system atrophy. *Arch Otolaryngol Head Neck Surg* 2002;128:1404-7
- [9] Vas CJ, Parsonage M, Lord OC. Parkinsonism associated with laryngeal spasm. *J Neurol Neurosurg Psychiatry* 1965;28:401-3
- [10] Read D, Young A. Stridor and parkinsonism. *Postgrad Med J* 1983;59:520-1
- [11] Corbin DOC, Williams AC. Stridor during dystonic phases of Parkinson's disease. *J Neurol Neurosurg Psychiatry* 1987;50:821-2
- [12] Lew MF, Shindo M, Moskowitz CB, Wilhelmsen KC, Fahn S, Waters CH. Adductor laryngeal breathing dystonia in a patient with lubag (X-linked dystonia-Parkinsonism syndrome). *Mov Disord* 1994;9:318-20
- [13] Nakane S, Motomura M, Furuya T, Shirabe S, Nakamura T. A case of juvenile Parkinson disease with vocal cord abductor paralysis in the course of malignant syndrome [in Japanese]. *Rinsho Shinkeigaku* 1999;39:370-2
- [14] Onoue H, Yukitake M, Kurohara K, Takasima H, Kuroda Y. A case report of Parkinson's disease presenting with recurrent dyspneic attacks due to focal laryngeal dystonia [in Japanese]. *Rinsho Shinkeigaku* 2003;43:192-4
- [15] Qayyum A, Mierzwa K, See M, Sharma A, Montgomery PQ. Laser arytenoidectomy for bilateral vocal fold palsy in Parkinson's disease. *J Laryngol Otol* 2005;119:831-3

We experience a difference in terms of managing our patient, a patient with stage 5 PD with bilateral vocal cord paralysis. She is bed ridden with low oxygen requirement despite having intermittent inspiratory stridor which was more pronounce when her Parkinson's symptoms exacerbated, with alteration and optimizing her antiparkinson's medication, her inspiratory stridor reduced significantly. Her baseline continuous oxygen saturation was seen to be more than 95% under room air. She was co-managed by neurology team in term of medical optimization. She was then followed up in our outpatient clinic to observe her symptoms.

CONCLUSION

In conclusion we would like to emphasize that it is important to recognize bilateral vocal cord paralysis in Parkinson's disease and early optimization of medical treatment could avoid a need of tracheostomy.

PATIENT CONSENT

Written informed consent was obtained from the patient for publication of this case report.

COMPETING INTERESTS

The authors declare no competing interests.