



ORIGINAL RESEARCH

**PENILE FRACTURE: EXPERIENCE FROM A
TERTIARY CARE HOSPITAL**

Malik Suhail AHMAD ¹ ; Irfan Nazir MIR ¹  ; Malik Faizan ABASS ²

¹ Department of Surgery, Government Medical College , Srinagar, Jammu and Kashmir, India

² Department of radiodiagnosis, Sher-i-Kashmir Institute of Medical Sciences , Srinagar, Jammu and Kashmir, India

ABSTRACT

Introduction: Penile fracture is a misnomer, penile fracture is defined as rupture of the tunica albuginea of one or both corpus cavernosum. The usual cause is abrupt bending of the erect penis by blunt trauma, which may occur during sexual intercourse, masturbation, rolling over on the bed or falling onto the erect penis. Diagnosis of penile fracture is made on the basis of history and physical examination. Standard mode of management is surgical.

Methods: This retrospective study was conducted in the department of surgery SMHS hospital Srinagar, (Jammu and Kashmir), extending over a period of about three and a half years from June 2013 to January 2017. All patients with diagnosed penile fracture were included in this study. All except one patient were operated on the same day of admission.

Results: Out of a total of 50 patients studied, the mean age of presentation was 26.7 years. Majority (56%) were below 30 years of age. 21 (42%) of the patients were married. Majority 42% of the patients reported masturbation as cause of trauma, followed by vaginal intercourse in 38% and rolling on erect penis in 20%. About 80% patients gave history of audible click/crackling sound. All patients had swelling and discoloration on examination, 90% patients had penile deformity, only 36% had palpable defect. Doppler USG was correct in 93% patients. Majority (44%) patients had defect less than 1 cm. Defect was mostly seen on right side (68%). Most patients had proximal penile defect (56%). Mean hospital stay was 2.9 days. One patient (2%) had urethral trauma. Surgery had a recurrence of 2% and a total postoperative complication rate of 10%.

Conclusions: Penile fracture though reported rarely, is a common entity. Penile fracture is a urological emergency. Diagnosis is mainly on clinical grounds. Immediate surgical repair is the standard treatment of penile fracture.

KEYWORDS: Penile fracture, Doppler USG, Masturbation.

Correspondence : Irfan Nazir MIR, Department of Surgery, Government Medical College, Srinagar, Jammu and Kashmir, India. E-mail : irfanazir@gmail.com

Copyright © 2019 Mir Irfan Nazir et al.

This is an open access article distributed under the [Creative Commons Attribution 4.0 International](https://creativecommons.org/licenses/by/4.0/), which permits unrestricted use, distribution, and reproduction in any medium, provided the original work is properly cited.

INTRODUCTION

Penile fracture is a misnomer; penile fracture is defined as rupture of the tunica albuginea of one or both corpus cavernosum. The usual cause is abrupt bending of the erect penis by blunt trauma, which may occur during sexual intercourse, masturbation, rolling over on the bed or falling onto the erect penis. Penile fracture is a

urological emergency and is under reported due to the shyness to describe it [1].

Patient usually presents with history of trauma to penis, hearing of an audible clicking sound followed by sudden detumescence. It can be associated with minimal or sharp pain in the penis. On examination swelling, ecchymosis,

penile deformity(known as egg plant deformity) are present [2].

Diagnosis of penile fracture is made on the basis of history and physical examination. However imaging techniques like USG and RGU can be used in case of doubt in diagnosis or suspected associated urethral injury [3].

The recommended procedure involves a degloving incision, evacuation of hematoma and repair of the rent of tunica albuginea with absorbable or non absorbable sutures. Other option is incision over shaft, directly overlying the penile fracture. This can be done only when fracture is palpable preoperatively [4].

MATERIAL AND METHODS

This study was a retrospective study conducted in the department of surgery SMHS hospital srinagar ,(Jammu and Kashmir), extending over a period of about three and a half years from june 2013 to January 2017 . All patients with diagnosed penile fracture were included in this study. Medical records of all these patients were studied retrospectively and data was recorded in predesigned proforma. Patients were diagnosed by history and examination . Doppler usg was also done in most of the cases . All except one patient were operated one the same day of admission. Surgery involves insertion of Foleys urethral catheter preoperatively in all patients without urethral injury and intraoperatively in the patients with urethral injury, subglanular degloving incision, identification of rent, evacuation of hematoma and closure of rent using absorbable suture(VICRYL) . Suppressive therapy in the form of oestrogen and phenobarbitone given for 2 week postoperatively. All patients were discharged with advice to avoid sexual intercourse for 2 months and patients were followed for a period of one year.

The follow up period in our study was 1 year. During this follow up period ,complete history and examination was done on each visit.History was taken regarding questions about erectile function, pain during intercourse, deformity and patients were also examined.the results were analysed and tabulated, appropriate statistical analysis were done.

RESULTS

A total of 50 patients were included in the study. The age of patients ranged from 16 to 50 years.Majority of the patients (56%) were between 16 and 30 years of age.The mean age of the patients was 26.7 years.only 6 (12%) patients were more than 46 years of age.(table 1).

Table-1 : Age distribution

Age at presentation	NO. Of patients	%
16-30	28	56
31-45	16	32
46-50	6	12

Only 21 (42%) of the patients were married whereas 29 (58%) were unmarried. (table 2)

Table-2 : Marital status

Marital status	No. Of patients	%
Married	21	42
Unmarried	29	58

Most of the patients 21(42%) had sustained the injury during masturbation,while penile fracture during vaginal intercourse or due to rolling over on erect penis was seen in 19(38%) and 10 (20%) patients respectively.(table 3)

Table -3 : Mechanism of injury

Mechanism of injury	No. Of patients	%
Vaginal intercourse	19	38
Masturbation	21	42
Rolling over on erect penis	10	20

About 80% of the patients described crackling sound in their history at the time of trauma.All patients (100%) presented with clinically evident swelling and discolouration in the penile shaft.While 45 (90%) patients had typical deformity upon clinical examination.only 18 (36%) patients had a palpable defect upon examination.(table 4)

Table-4 clinical features

Clinical features	No. Of patients	%
Crackling sound	40	80
Swelling	50	100
Discolouration	50	100
Palpable defect	18	36
Penile deformity	45	90

Penile Doppler was done in 45 cases, out of these 45 ,in 42 (93%) of the patients the defect was picked up by Doppler , while in 3 (7%) patients in whom Doppler was negative , surgery was carried out on basis of strong clinical findings , and the defects could well be located intraoperatively, 1 patient was managed conservatively as he presented late and had clinical improvement (table 5). The size of the defects in the patients in our study as observed and estimated intraoperatively or on USG were 0.5 - 1 cm in 44% patients, 1 – 1.5 cm in 28% patients, and > 1.5 cm in 28% patients. Side of the defect in tunica albuginea, was Right side in 34 (68%) patients, left side in16 (32%) patient. The site of tunica rent was ,at the proximal part of penis in 31 (56%) patients, mid portion in 14(28%) patients, distal part in5(10%) patients.

Table-5 : Doppler findings

Penile Doppler	No. Of patients	%
Defect picked	42(45)	93
Defect not picked	3(45)	7

Out of a total of 50 patients , only 1(2%) patient was managed conservatively, while rest 49 (98%) underwent emergency surgery within 12 hours of admission.All patients were operated by similar technique as described in material methods.One patient (2%) had urethral injury ,which was repaired on table,using absorbable sutures over a foley catheter. In our study 44 (88%) patients were discharged from hospital between 2-4 days,Mean hospital stay was 2.9 days. Only 6 patients were discharged

between 6 to 11 days. Among the operated patients (49/50), about 8.2% patients developed wound infection, while 4.1% developed flap necrosis, recurrence was seen in 1 patient after surgery and was managed by second surgery, while as approximately 6 patients complained of erectile dysfunction which was managed conservatively, by medicine, perineal exercise and reassurance. (table 6)

Table-6 : Complications

Early complications	NO. Of patients	%
Wound infection	4	8.2
Flap Necrosis	2	4.1
Late complications	NO. Of patients	%
Recurrence	1	2
Erectile dysfunction	3	6

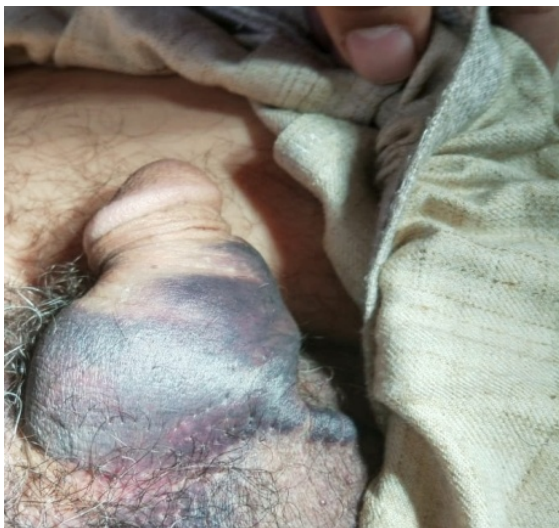

Figure 1 – Pre operative

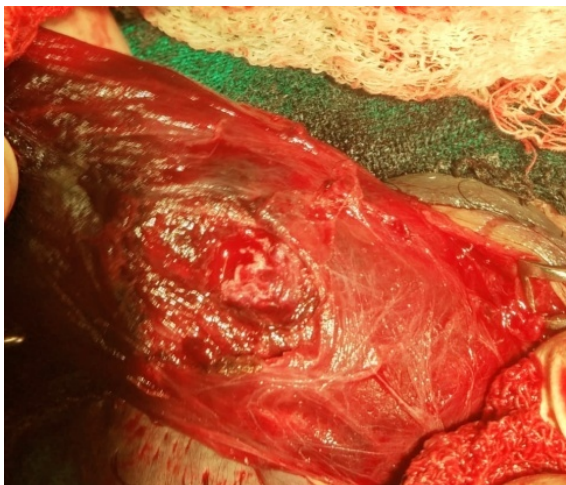


Figure 2 : Intraoperative

DISCUSSION

Penile fracture has typical clinical signs reported as trauma to the penis, audible clicking sound, post erection detumescence with hematoma and swelling. Penile fracture is an entity of eminently clinical diagnosis, therefore the management of a penile fracture should not include any further investigation other than surgical exploration.

The age of the patients in our study was in the range of 16 - 50 years. The mean age of the patients in our study was 26.7 years. Majority of the patients were in the range of 16-30 years, 28 patients were in this range (56%). This is comparable to the studies by Paul D, Ekwere et al [5] and Z Athar et al [6] and Benefelloun M et al [7].

In our study 21(42%) patients were married and 29(58%) were unmarried. this is comparable to studies by Paul Ekwere et al [5] and Z-Athar et al [6].

The most common aetiology was masturbation in 21 (42%), followed by intercourse in 19 (38%) patients, and rolling over or fall on erect penis in 10 (20%) patients. This is comparable to study by Taha Ab. Abdel Nasser, M.D et al [8] and Hung Jen Shih et al [9]. During intercourse the fracture of the penis would occur as penis slips out of the vagina and is thrust against the perineum or symphysis pubis vigorously. The reported incidence of the various etiological factors for penile fracture varies because patients do not always accurately report the cause, probably due to embarrassment.

Patients presenting to emergency departmental in our study were having the clinical features of: Swelling in 50(100%) patients, pain in 40(80%) patients, deformity in 45 (90 %) patients, ecchymosis in 50 (100%) patients and cracking sound in 40 (80%) patients. these results are similar to the study conducted by Imtiyaz Wani [10] ; Rooh-ul-Muquim et al [11] Gregory S et al [12] and Paul D Ekwere et al [5].

The size of the defects in the patients in our study as observed and estimated intraoperatively or on USG were 0.5 - 1 cm in 44% patients, 1 - 1.5 cm in 28% patients, and > 1.5 cm in 28% patients. the study carried by Abdullah Gedik et al [13] presenting a study of 107 cases with size in range of 0.5 - 1 cm (35.7%), 1 - 2 cm (60.4%) and 2 - 4 cm (39%).

Side of the defect in tunica albuginea, in our study was Right side in 34 (68%) patients, left side in 16 (32%) patient. these results are nearly in accordance to the study conducted by Paul D Ekwere et al [5] ; Z Athar et al [6].

The site of tunica rent in our study was, at the proximal part of penis in 31 (56%) patients, mid portion in 14 (28%) patients, distal part in 5(10%) patients. this is comparable with the study conducted by Imtiyaz Wani [10] and Paul D Ekwere [5] .

In our study one patient (2%), had urethral injury. The incidence of urethral injury associated with penile fracture is reported as 2-3% in Asia and Middle East. Soyly A et al ¹⁴ and Derouche A et al [15].

In our study 44 (88%) patients were discharged from hospital between 2-4 days, Mean hospital stay was 2.9 days. Only 6 patients were discharged between 6 to 11 days because 4 had wound infection at the incision site which was managed conservatively and other 2 had skin gangrene which settled after wound debridement. Hospital stay is comparable to study carried by GV Soundra Pandyan et al [16] and Paul D Ekwere [5].

In our study 10 patients had complication. four of our patients had wound infection, which were managed conservatively. Two of our patients had penile skin gangrene which settled after wound debridement. Three

of our patients had painful erection or loss of libido which settled down without medication. One of our patient had recurrence, which was managed by surgery. So in our study complication were found in 10 (20%) patients. these results were comparable to study conducted by G.V Soundra Pandyan et al [16].

The follow up period in our study was 1 year. Most of the patients regained the sexual function within 8-10 weeks with only 3 patient requiring upto six months for the sexual function to regain to normal.

AUTHORS' CONTRIBUTIONS

The participation of each author corresponds to the criteria of authorship and contributorship emphasized in the [Recommendations for the Conduct, Reporting, Editing, and Publication of Scholarly work in Medical Journals](#) of the [International Committee of Medical Journal Editors](#). Indeed, all the authors have actively participated in the redaction, the revision of the

REFERENCES

- [1] Bhuyian ZH, Khan SA, Tawhid MH, Islam MF. Personal series with clinical review of fracture penis. *Mymensingh Med J* 2007;16:187-90.
- [2] Eke N. Fracture of penis. *Br J Surg* 2002; 89:555-65
- [3] Koga S, Saito Y, arakaki Y, Nakamura N, Matsuoka M, Saita H, et al sonography in fracture of penis. *Br j urol* 1993;72:228-9
- [4] Jack GS, Garraway I, Reznick R, Rajfer J. Current treatment options for penile fracture. *Rev urol* 2004;6:114-20
- [5] Paul D. Ekwere FRCS and Mohammed Al-Rashid FRCS. Trends in the incidence, clinical presentation and management of traumatic rupture of the corpus cavernosum. *Journal of the National Medical Association* Feb. 2004; Vol. 96, No. 2: 229-233
- [6] Z Athar, PR Chalise, UK Sharma, PR Gyawali, GK Shrestha and BR Joshi. Penile fracture at Tribhuvan University Teaching Hospital. A retrospective analysis. *Nepal Med Coll J* 2010; 12(2):66-68.
- [7] Benefelloun M, Rabii R, Bennani S, Querfani B, Jonal A, El Mrini MN. Fracture of the corpus cavernosum: report of 123 cases. *Afr J Urol* 2003; 9:1-10.
- [8] Taha Abdel Nasser, MD, and Taymour Mostafa, MD. Delayed surgical repair of penile fracture under local Anaesthesia. *Journal OF Sexual Medicine* 2008; 5:2464-2469.
- [9] Hung-Jen Shih, Wen-Chou Lin, Huang-Kuang Chang, Stone Yang, Jong-Ming Hsu, Marcelo Chen, Wei-Kung Tsai. Penile fracture: Analysis of 13 patients a literature review. *JTUA* 2007;18:99-101.
- [10] Imtiaz Wani. Management of penile fracture. *Oman Medical Journal* July 2008; Vol. 23: issue 3: Page 162-165.
- [11] Rooh-ul-Muqim, Qutb-e-Alam Jan and Mohammad Zarin. Management of penile fracture. *Pak J Med Sci* Jan-Mar 2006; Vol. 22, No. 1: 23-27.
- [12] Gregory S, Jack M, Garraway I, Reznick R, Rajfer J. Current treatment options for penile fracture. *Rev Urol* 2004; 6:114-20.
- [13] Abdullah Gedik, Devrim Kayan, Sait Yilmaz, Kamuran Bircan. The diagnosis and treatment of penile fracture: Our 19 year experience. *Turkish Journal Trauma and Emergency Surgery* 2011; 17(1):57-60.
- [14] Soylu A, Yilmaz U, Davarci M, Baydinc C. Bilateral disruption of corpus cavernosum with complete urethral rupture. *Int J Urol* 2004; 11:811-2.
- [15] Derouche A, Belhaj K, Hentali H, Hafsia G, Shama MR, Chelbil M. Management of penile fractures complicated by urethral rupture. *Int J Impot Res* 2008; 20:111-4. Epub 2007 Aug 2.
- [16] G.V. Soundra Pandyan, Ahmed Bakeet Zaharani, and Mohammed Al Rashid. Fracture penis: An analysis of 26 Cases. *the Scientific World Journal* (2006) 6, 2327-2333.

CONCLUSION

Penile fracture though reported rarely, is a common entity. Penile fracture is a urological emergency. Diagnosis is mainly on clinical grounds. Immediate surgical repair is the standard treatment of penile fracture. We recommend immediate exploration, evacuation of haematoma and repair of the defect in the tunica albuginea as the treatment of choice.

manuscript and provided approval for this final revised version.

ETHICAL APPROVAL: The study was approved by the Institutional Ethics Committee.

COMPETING INTERESTS

The authors declare no competing interests.